

Mini Review

Oral Manifestations in Diabetes Mellitus

Krishnanjali Babu, Krithika Adiga, Lenita Dsouza, Preethi Poonja*, Gowri Bhandarkar, Prasanna Kumar Rao and Raghavendra Kini

Department of Oral Medicine and Radiology, A.J Institute of Dental Sciences, Mangalore, Karnataka, India

Abstract

Diabetes mellitus is a chronic disease affecting all age groups. It is one of the leading causes for mortality and morbidity worldwide. Many chronic macrovascular and microvascular complications of diabetes have been reported in the literature with few reports about oral complication. This article aims to review and increase the awareness of oral manifestation of diabetes. It deals in depth of complication such as periodontal disease, fungal infection and salivary dysfunction.

Keywords: Diabetes mellitus; Oral complication; Periodontal disease; Fungal disease

Introduction

Diabetes mellitus is a multifactorial, complex, genetically derived endocrine disorder. It is a syndrome of impaired carbohydrates, fats and protein metabolism caused either by lack of insulin secretion or decreased sensitivity of tissues to insulin. It represents an abnormality in glucose metabolism due to an insulin deficiency, impaired utilization of insulin or an error in insulin metabolism. Diabetes affects all age group, but is more common in adults [1]. The World Health Organization (WHO) has recently declared it to be pandemic, its prevalence has increased dramatically over the past few decades and it is expected to triple in next decade. The most common types of diabetes are Type-1(also known as insulin-dependent) and Type-2(also known as non-insulin dependent); Type-2 is the prevalent type. The common characteristic of this condition is elevated blood glucose level (hyperglycemia) [2].

Oral Manifestations of Diabetes

Effects on periodontium

Patient with diabetes mellitus is more prone to develop periodontal disease than are those with normal glucose metabolism. As such diabetes does not cause periodontal disease directly but it alters the response of periodontal lesion to local irritants, hastening of bone loss and retarding post surgical healing of the periodontal lesion. Also gingival fluid in diabetes has more glucose level which favors the growth of microflora [1]. Diabetes may complicate the pathogenesis of periodontitis by:

- Causing abnormalities in the vasculature of the gingival tissue
- Deregulating the normal production of cytokines and growth factors, decreasing the synthesis and cross-linking of collagen, i.e., Advanced Glycosylation End Products (AGES)
- Increasing collagenase levels

Citation: Babu K, Krithika A, Dsouza L, Preethi P, Bhandarkar G, Rao PK, et al. Oral Manifestations in Diabetes Mellitus. Dentist. 2019; 1(2): 1008.

Copyright: © 2019 Krishnanjali Babu

Publisher Name: Medtext Publications LLC

Manuscript compiled: August 12th, 2019

***Corresponding author:** Preethi Poonja, Department of Oral Medicine and Radiology, A.J Institute of Dental Sciences, NH 66, Kuntikana, Mangalore, Karnataka, India, Tel: 7829902361; E-mail: preetipoonja@gmail.com

- Depressing immune response
- Change in host-defense mechanism
- Changes in function of host defense cells such as polymorphonuclear leukocytes, monocytes and macrophages
- Chemotaxis and phagocytosis are impaired [3].

These aspects give raise to gingivitis which will proceed to periodontal issues like recession, furcation and bone loss which leads to mobility (Figure 1).

Periodontitis

Patient may exhibit fulminating periodontitis with periodontal abscess formation. This will give rise to mobility of teeth, there is severe and rapid alveolar bone resorption taking place (Figure 2) [3].

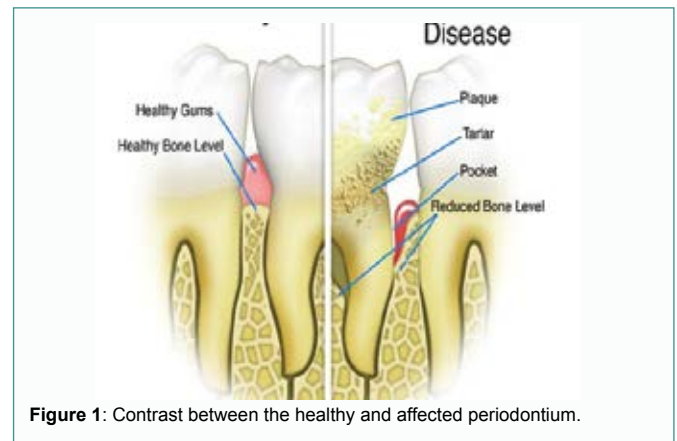


Figure 1: Contrast between the healthy and affected periodontium.

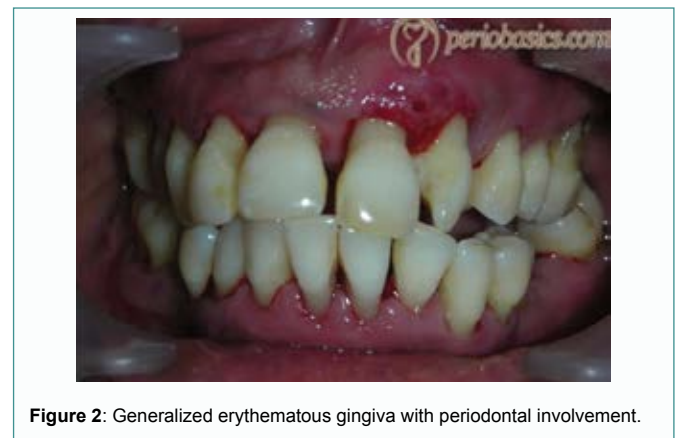

Figure 2: Generalized erythematous gingiva with periodontal involvement.

The formation of advanced glycosylated end product (glucose + hemoglobin)

Results in collagen accumulation in the periodontal capillary basement membranes



Causing membrane thickening and narrowing of the vessel lumen



Decreases oxygenation of the tissues



Alter the tissue response to periodontal pathogens



Resulting in increased tissue destruction and diminished repair potential [4].

Oral candidiasis

It is infection caused due to Candida Albicans which occurs due to encouragement of local multiplication of Candida Albicans due to impaired glucose level and immune mechanism [3].

Presence of local oral factors such as dentures also engenders to candidal infections [4].

Candidiasis clinically appears as a white patch which are scarp able (Figure 3).

Poor glyceimic control



Leads to dry mouth



Increased density of candida species



Leads to oral candidiasis.

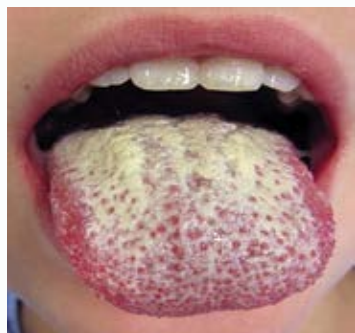

Figure 3: White homogenous patches on dorsal surface of tongue.

Localized osteitis

Dry socket develops in diabetes; hence show delayed healing and impaired immune logical balance.

Localized osteitis caused mainly due to [5].

- Increased production of Matrix Metalloproteinases (MMPs) such as collagenase [3].

- Decreased level of anabolic bone hormone called as Osteocalcin which is a gamma-carboxy glutamate protein [6].

Burning mouth

It is often associated with variety of otherwise unexplained oral symptoms like burning sensation, atypical paresis, dysesthesia and dysguesia caused mainly due to,

- Xerostomia
- Peripheral neuropathy
- Poor oral hygiene
- Candidiasis [4].

Trigeminal nerve involvement

Diabetes neuropathy is recognized as polymorphic condition as when manifested as poly neuropathy as the assumption that trigeminal nerve might be involved [3].

Increased caries activity

There is also increased caries activity due to (Figure 4).

- Xerostomia
- Increased glucose in saliva and GCF, which stimulates bacteria to accumulate
- Thick saliva due to excess glucose
- Decreased flushing action due to neuropathy [4].

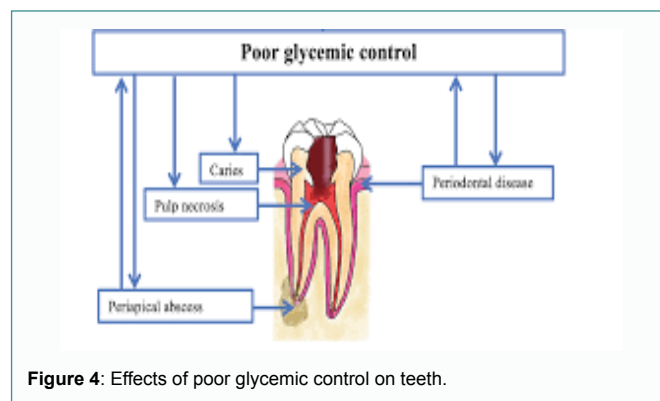


Figure 4: Effects of poor glyceimic control on teeth.

Delayed healing

There is delay in healing of oral wounds due to decrease in polymorphonuclear chemotaxis.

- Hyperglycemia results in increased GCF glucose levels which alters the interaction between cells and their extracellular matrix within the periodontium.
- Increased production of matrix metalloproteinases (MMPs) such as collagenase [4].

Diabetic sialadenosis

In diabetic patients, there is also diffuse nontender bilateral enlargement of parotid gland [3].

Disturbances in the autonomic sympathetic innervations



Causes dysregulation of protein synthesis



Causes cytoplasmic swelling due to enlargement by intra-cytoplasmic zygomen granules within ductal acini



Causes salivary gland enlargement [4].

Xerostomia

Xerostomia (dry mouth) is caused due to

- Side effect to medicines used by patient such as metformin (Oral medication for diabetes)
- Neuropathy-causes change in sympathetic and parasympathetic flow
- Age related (both xerostomia and diabetes occurs in older age) [3].

Oral mucosal lesions

- Oral lichen planus-greenspan syndrome
- Candidiasis caused due to xerostomia, immunosuppression, poor oral hygiene and increase in glycosylated hemoglobin [3].

Conclusion

Prevention and management of oral complications, especially periodontal disease, in patients with diabetes is important due to their possible adverse effect on glycemic control. Similarly, treatment of oral diseases include systemic evaluation of patients for diabetes to achieve successful results, both disease should be controlled and treated properly when they occur as co-morbid conditions.

References

1. Indurkar MS, Arati SM, Sanjiv I. Oral manifestation in diabetes. Clin Diabetes. 2016;34(1):54-7.
2. Miller LS, Manwell MA, Newbold D, Reding ME, Rasheed A, Blodgett J, et al. The relationship between reduction in periodontal inflammation and diabetes control. J Periodontol. 1992;63(10):843-8.
3. Textbook of oral medicine-Anil G R and Savita AG (Third Edition).
4. Textbook of oral medicine and radiology-Peeyush S (First Edition).
5. Arvind P, Mohan V, Krishnamurthy V. Rheumatological manifestation of diabetic mellitus. J App Med. 1991.
6. Soysa NS, Samaranayake LP, Ellepola AN. Diabetes mellitus as a contributory factor in oral candidiasis. Diabet Med. 2006;23(5):455-9.