

## Research Article

# Outcome of Sclerokeratoplasty in Quiescent Corneal Pathologies

Thatte Shreya\* and Krishnan Malvika

Department of Ophthalmology, Sri Aurobindo Medical College and PG Institute, India

## Abstract

**Introduction:** Corneal blindness is a leading cause of preventable blindness in the world. Quiescent full thickness corneal pathologies involving one or more quadrants of the limbus, obscuring the visual axis can be managed only by sclerokeratoplasty. It poses more challenges compared to simple penetrating keratoplasty as large sized corneoscleral grafts involve greater complexity in achieving desired cosmetic and optical results due to loss of limbic support, limbal vascularisation and distortion of angle structures.

**Material and methods:** This is a prospective interventional study done on 35 eyes with quiescent corneal pathologies involving one or more quadrants of the limbus, all of which underwent sclerokeratoplasty with certain modifications. The corneal pathologies included in our study were simple corneal opacity, adherent leucoma and anterior staphyloma.

**Results:** The primary goal of our study is to obtain cosmetic and optical results, which was achieved in 28 (80%) cases of the total 35 (100%) cases. Of the remaining 7 (20%) cases, visual outcome was not obtained cause of a hazy graft in 4 (11.42%) cases because of residual central stromal corneal haze post complete healing after graft rejection, graft failure and graft neovascularisation and the remaining 3 (8.57%) cases showed clear grafts but optical results were not achieved in these cases due to posterior segment pathologies.

**Conclusion:** Sclerokeratoplasty in quiescent corneal pathologies gives optimum optical and cosmetic results with respect to graft clarity and best corrected visual acuity. This can be achieved with elaborate preoperative work up including UBM, intraoperative modifications, post-operative care and regular follow up.

**Keywords:** Reconstructive keratoplasty; Sclerokeratoplasty; Quiescent corneal pathologies; Corneal opacities; Anterior staphyloma; Adherent leucoma; Ultrasound biomicroscopy; Gonioscopy

## Abbreviations

IOP: Intraocular Pressure; UBM: Ultrasound-biomicroscopy; IOL: Intra-ocular Implant; BCVA: Best Corrected Visual Acuity; HM: Hand Movement; PSPK: Penetrating Sclerokeratoplasty

## Introduction

Corneal blindness is a major cause of preventable blindness world wide, also contributing as a challenging public health problem all over the world. Hence, the public health significance of corneal transplantation in dealing with corneal blindness depends upon the survival rates of these transplants.

A full thickness healed corneal scar, obscuring the visual axis and limiting vision sufficiently, can be managed only by penetrating keratoplasty. These corneal pathologies if involve one or more quadrants of the limbus, require a modified technique of sclerokeratoplasty.

Sclerokeratoplasty is more challenging than simple penetrating keratoplasty, as there is involvement of the angle structures. Hence it requires certain modifications during the intraoperative surgical

steps, post-operative management and during follow-up, in order to obtain a desired visual outcome.

Therefore, this study was undertaken to recognize the intraoperative challenges, post-operative complications of sclerokeratoplasty and factors responsible for surgical outcome in quiescent corneal pathologies. These corneal pathologies include full thickness simple corneal opacity, adherent leucoma and anterior staphyloma.

## Materials and Methods

**Study design:** Prospective interventional study

This study was undertaken according to Helsinki Declaration after clearance from ethics committee. (Ref No-ECR/748/Inst/MP2015). It included 35 eyes of 35 patients with healed corneal pathologies involving the limbus.

### Inclusion criteria

- 1) Healed full thickness corneal pathologies involving the limbus
- 2) No active inflammation or infection
- 3) Healthy ocular surface
- 4) Accurate perception and projection of light in all directions.
- 5) No involvement of posterior segment on B-scan

### Exclusion criteria

- 1) Healed Corneal pathologies with absence of involvement of limbus
- 2) Central corneal opacities.

**Citation:** Shreya T, Malvika K. Outcome of Sclerokeratoplasty in Quiescent Corneal Pathologies. Clin Ophthalmol J. 2020;1(3):1013.

**Copyright:** © 2020 Thatte Shreya

**Publisher Name:** Medtext Publications LLC

**Manuscript compiled:** Oct 28<sup>th</sup>, 2020

**\*Corresponding author:** Shreya Thatte, Department of Ophthalmology, Sri Aurobindo Medical College and PG Institute, Indore -452001, Madhya Pradesh, India, Tel: +919302104864; E-mail: shreyathatte@gmail.com

- 3) Active pathology.
- 4) Dystrophies of the cornea.
- 5) Inaccurate perception and projection of light in all direction.
- 6) Posterior segment involvement due to infective pathology.

### Pre-operative regime

All patients were questioned in detail about the history, course and treatment of the corneal pathology. Other significant past medical or surgical ocular treatment was noted to understand the etiopathogenesis of the pathology.

A total of 35 patients were selected of healed corneal pathologies involving the limbus. All patients were divided into three groups on basis of corneal pathology.

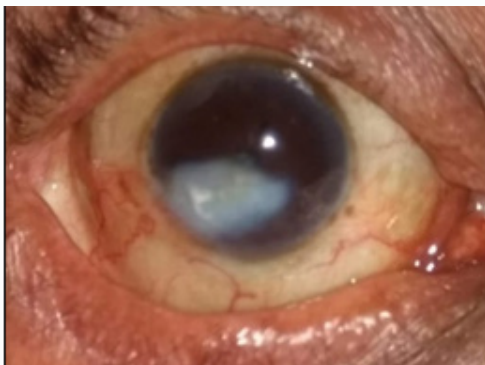
**Group A:** Simple full thickness corneal opacity (Figure 1a)

**Group B:** Adherent leucoma (Figure 1b)

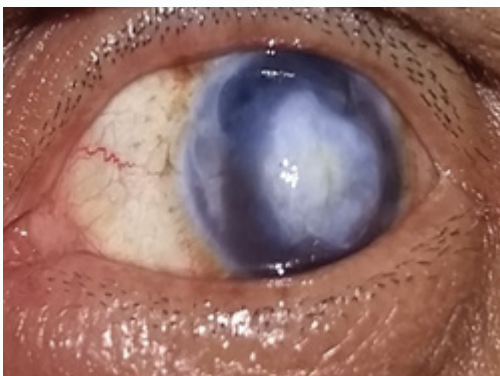
**Group C:** Anterior staphyloma (Figure 1c)

They underwent routine ocular examination including visual acuity in both eyes; projection and perception of light rays and corneal sensations were checked to rule out any underlying neurological cause. A detailed slit lamp examination was conducted of the lid, adnexa and other anterior segment structures. Minute details of the corneal scar were evaluated noting its size, depth and extent of limbal involvement.

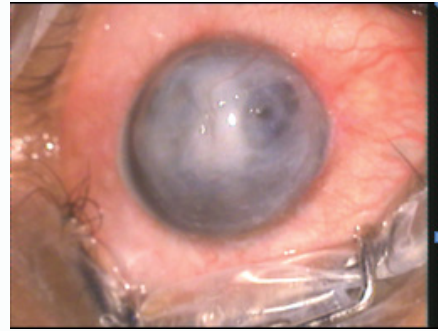
Certain special investigations like Ultrasound-Biomicroscopy (UBM) and B-scan revealed the details of the anterior and posterior segment respectively, which were concealed behind the corneal scar.



**Figure 1a:** Pre-operative picture of a case of a full thickness simple corneal opacity.



**Figure 1b:** Pre-operative picture of a case of adherent leucoma.



**Figure 1c:** Pre-operative picture of a case of anterior staphyloma.

UBM was helpful in knowing, the exact depth and extent of corneal scarring, anterior and posterior synechia formation, and depth of anterior chamber at various quadrants and status of pupil, lens and angle of anterior chamber. Hence aiding as a useful tool in planning the surgery, predicting the intraoperative surgical modifications required and explaining the prognosis to the patient.

In all patients Intraocular Pressure (IOP) was recorded by applanation tonometry and Gonioscopy was performed. Cases, whose intraocular-pressure was found to be within 30 mm of Hg, were treated with topical anti-glaucoma medications and systemic carbonic anhydrase inhibitors. Intraocular pressure if noted to be above 30 mm of Hg, intravenous mannitol 20%, 1 gm per kg body weight was given preoperatively. Considering the IOP and findings noted on gonioscopy, patients were planned accordingly for sclerokeratoplasty with trabeculectomy.

All patients were give topical antibiotics and in the presences of synechia, cycloplegics were added.

Patients underwent systemic examination and special investigations to procure a physicians fitness. A written informed consent was taken from the patients and relatives, who were also counselled about the procedure, its associated complications, guarded prognosis, requirement for subsequent procedures, necessity of an excellent compliance and a regular follow up for a long period post-operatively.

Pre-operative and post-operative clinical photographs/intra-operative surgical videos were taken for documentation, of all the patients and penetrating sclerokeratoplasty was carried out in all cases by a single surgeon.

### Surgical procedures

Surgery was done under local anesthesia in most of the cases. Young children and unco-operative patients were operated under general anesthesia, under all aseptic precautions.

Painting and draping was done under sterile field with 5% povidone iodine and lid speculum placed for adequate exposure.

Conjunctival peritomy was carried out at the site of the sclero-corneal involvement. All procedures were planned as per the findings confirmed on slit lamp and UBM. As per UBM findings, a pre-decided trephine size was confirmed on table and the scarred corneal host tissue was marked.

Anterior chamber was penetrated at maximum anterior chamber depth as per the UBM findings. All Groups A cases showed good anterior chamber depth where entry was made as per surgeon's

convenience. In group B and C care was taken during entry into the anterior chamber so as to avoid damage to the iris-lens diaphragm and prevent its self extrusion.

The recipient host tissue was cut with the help of a Wertheim's corneal scissor and synechiolysis was performed, at the site of the synechia, as per findings confirmed on UBM. The contact synechia, adherent leucoma and incarcerated iris were released by means of a stick swab, iris repositor and corneal vanna's scissors respectively from the host corneal tissue taking care to minimally damage the iris.

During excision of the host corneal tissue, at sites of limbal involvement, the edges of the host corneal tissue were excised obliquely, keeping the base towards the sclera and the slope towards the iris, as to avoid the destruction of the angle structures. Similarly, the donor tissue was excised obliquely but in a reverse manner, for proper fitting of the graft on recipient bed. Peripheral iridectomy was performed in all eyes to avoid postoperative glaucoma.

In patients with dense cataract, simultaneous lens extraction was executed. In cases showing a good posterior support, posterior chamber intraocular lens was implanted. In conditions of anterior staphyloma, where lens subluxation or extrusion was seen, lensectomy was performed and patients were kept for secondary intra ocular lens implantation.

Some other intra-operative surgical modifications like pupillary membrane removal, iris and pupillary reconstruction were also carried out with 10-0 prolene suture with straight needle in accordance to the case.

The donor graft size varied with limbal involvement, with the graft being kept half mm larger than the host corneal scar and in cases with more than 10 mm diameter of corneal involvement, the donor graft was kept 1mm larger than the host defect. The suturing of the donor cornea was done using 10-0 nylon with 4 cardinal stay sutures were placed followed by 16 interrupted sutures. The suture knots were buried away from the limbus. Sutures at the corneo-scleral junction were taken little longer, for proper tightening effect and they were super-imposed with a conjunctival flap.

Anterior chamber was formed with normal saline or air. Subconjunctival injection of gentamicin and dexamethasone was given in all patients.

### Post-operative

In all cases systemic antibiotics and steroids were given as per patients body weight from day one and tapered down postoperatively. Patients were also advised topical antibiotics and topical steroids 2 hourly initially and further tapered in dose and frequency according to the condition of the eye. Apart from it cycloplegics were also given postoperatively over two to three months along with lubricating eye drops over a year and anti glaucoma medications as per requirement.

### Follow-up

During follow-up, patients were kept under close observation for graft clarity, visual acuity, IOP, suture related complications, signs of persistent inflammation, wound dehiscence, vascularisation, anterior chamber reaction, graft rejection and they were instructed to report immediately if any signs such as blurring of vision, redness or pain were seen.

Follow-up was done weekly for a month, further every 15 days for next 3 months and monthly for a year and then follow-up kept every

3 monthly through a year's time.

Due to limbal involvement, there is an increased risk of immunological graft rejection and in uneventful follow-up; patients were kept on topical steroids once daily for a year.

In cases of early signs of graft rejection patients were given three pulse doses of 500 mg intravenous methyl prednisolone and cases who still did not respond were started on systemic immune-suppressants such as oral azathioprine and topical and systemic cyclosporine's, after fitness from the physician.

## Results

Descriptive statistical analysis was used to calculate the percentage frequency of the variables.

Out of the total 35 cases, a male preponderance with 20(57.14%) cases was seen with the remaining 15(42.85%) cases belonging to the female population. Maximum cases of both male and female population accounting to 9 (25.71%) and 6(17.14%) cases were seen to lie between the age group of 45 to 55 years adding to a total of 15 (42.85%) cases in the age group (Table 1).

Overall out of the total of 35 cases, 13(37.14%) cases of Group A made a majority, followed by 12 (34.28%) cases belonged to Group B and Group C comprised of the remaining 10 (28.57%) cases.

It was noted that most commonly graft size ranged from 7.5 mm to 9.5 mm seen in 40% (14) of the total cases, with 28.57% (10) cases belonging to Group A. There were a total of (12) 34.28% cases with graft size ranging from 10.5 mm to 12.0 mm of which a majority of 6 (17.14%) cases belonged to group B. The rest 9 (25.71%) cases noted a graft size ranging from 9.0 mm to 10.5 mm of which a majority of 4 (11.42%) cases belonged group B (Table 2).

The above table shows that maximum cases had a two quadrant limbal involvement that is as seen in 18 (51.42%) cases, of which 8 (22.85%) cases were of Group A, 7 (20%) cases of Group B and 3 (8.57%) cases of Group C.

A three quadrant limbal involvement was seen in 9 (25.71%) cases and one quadrant limbal involvement was seen in 8 (22.85%) cases (Table 3).

Findings of UBM and Gonioscopy confirmed the anterior chamber depth in all the cases. It was found that 10 (28.57%) patients all of group A showed a grade 4 on von-hericks and a majority of 4 (11.42%) cases of group B of the total 7 (20%) cases showed a grade 0 on von hericks (Table 4).

On examination it was found that 9 (25.71%) cases of group B and 6 (17.14%) cases of group C were associated with anterior synechia formation and on UBM ,it was further confirmed , with 6 (17.14%) cases showing involvement along 6 to 9 o'clock hours and 4 (11.42%) cases showed involvement along 3 to 6 and 6 to 9 o'clock hours. Only 1 (2.85%) case of group B and group C showed a 180 degree and 360 degree anterior synechia formation respectively. Also with UBM we could confirm that 3 cases solely of Group A noted to show a posterior synechia formation (Table 5).

Among the total 35 cases, 12 (34.28%) cases showed early cataractous changes. The remaining 10 (28.57%) cases showed dense cataractous changes, of which 7 cases underwent a cataract extraction with simple posterior chamber intraocular lens implantation, 1 (2.85%) case was left aphakic intraoperatively following which managed

with vitrectomy and an aniridia intraocular lens implantation. The remaining 2 (5.71%) cases of the 10 showed a disruption in the structures of the angle of the anterior chamber and thus were left untouched intraoperatively. Following which on a 6 month follow-up with a clear graft and no other associated complications they were taken for a posterior chamber intraocular lens implantation.

There was 1 (2.85%) case of group C which showed a one quadrant subluxation of lens, but the lens position was stable and therefore it was left untouched. Also 1 (2.85%) case of group B which showed a posterior dislocation of lens was managed post-operatively at a 6 month follow-up with a posterior chamber intraocular lens implantation by the retina unit (Table 6).

The above table displays the modifications or additional procedures required during surgery in all the cases in order to enhance the final outcome of surgery are mentioned. In majority of patients more than one modification had to be done simultaneously in individual case. Release of anterior and posterior synechia were required in a total of 18 (51.42%) cases of which majority of 9 (25.71%) cases belonged to group B. A pupillary membrane removal was seen in a total 16 (45.71%) cases with a majority similarly noted in cases of group B accounting to 7 (20%) cases. Similarly iris reconstruction was also seen to be required in a majority of 4 (8.75%) cases of group B of the total 7 (20%) cases. The table also details clearly that a least amount of modifications and additional procedures were noted in cases of group A (Table 7).

Above table depicts many complications faced in immediate postoperative period. Among these shallowing of the anterior chamber was most commonly seen in 8 (11.85%) cases managed

**Table 1:** Age and gender wise distribution of cases.

Age group in years	Number of males (no-20)	Number of females (no-15)	Total (no-35)
25-35	2	2	4
35-45	2	3	5
45-55	9	6	15
55-65	6	3	9
65-75	1	1	1
Total	20 (57.14%)	15 (42.85%)	35

**Table 2:** Distribution of graft sizes.

Donor graft size (mm)	Group A	Group B	Group C	Total
7.5-9.0	10 (28.57%)	2 (5.71%)	2 (5.71%)	14 (40%)
9.0-10.5	2 (5.71%)	4 (11.42%)	3 (8.57%)	09 (25.71%)
10.5-12.0	1 (2.85%)	6 (17.14%)	5 (14.28%)	12 (34.28%)
Total	13	12	10	35

**Table 3:** Limbal quadrant involvement in different pathologies.

Limbal quadrant involvement	Group A (no-13)	Group B (no-12)	Group C (no-10)	Total (no-35)
One quadrant	4	1	3	8 (22.85%)
Two quadrant	8	7	3	18 (51.42%)
Three quadrant	1	4	4	9 (25.71%)
Total	13 (37.14%)	12 (34.28%)	10 (28.57%)	35 (100%)

**Table 4:** Anterior chamber depth according to different to different corneal pathologies.

Anterior chamber depth (Von hericks grading)	Group A (n-13)	Group B (n-12)	Group C (n-10)	Total
0	0	4	3	7 (20%)
1	0	5	2	7 (20%)
2	0	2	4	6 (17.14%)
3	3	1	1	4 (11.42%)
4	10	0	0	10 (28.57%)
Total	13	12	10	35

by air injection. It was noted that 6 (17.14%) cases showed suture related complication. Early Graft rejection was seen in 5 (14.28%) cases of which 4 cases were managed medically with I/V methyl prednisolone pulse dose of 1 gm per day given for 3 days followed by which patients were started on oral prednisolone 1mg/kg body weight tapered gradually along-side topical steroids tapered as per patients requirement, with reversal of graft rejection seen in 4 cases and graft failure seen only in 1 case.

Also all our cases were preoperatively thoroughly evaluated with UBM and Gonioscopy and only 3 cases of were diagnosed with glaucoma which were all managed with trabeculectomy and hence no incidence of intraoperative complications and post-operative glaucoma were encountered (Table 8).

The above table illustrates the Best Corrected Visual Acuity (BCVA) in 35 cases, with 28 cases showing a desirable visual outcome of 6/60 and above of which a majority of 20 (57.14%) cases showed it to be between 6/60 and 6/24, 8 (22.85%) cases showed it to be 6/18 and above, the remaining 7 (20%) cases did not obtain a desired visual outcome with BCVA seen to be between HM and 5/60.

It was also noted that out of a total of 35 cases 31 (88.57%) cases showed clear grafts, with a desirable visual outcome obtained in 28 (80%) cases with BCVA of 6/60 and above of which a majority of 12 (34.28%) cases belonged to group A, followed by 10 (28.57%) and 9 (25.71%) cases belonging to group B and group C respectively. A Desired Visual outcome was not obtained in 3 (8.71%) cases with clear grafts with BCVA between HM and 5/60 due to posterior segment pathologies such as a macular scar in a case belonging to group A and one case glaucomatous optic atrophy belonging to group B and C each.

Hazy grafts were found in a total of 4 (11.42%) cases of which 2 (5.71%) cases belonged to group B and 1 (2.85%) case each of group A and group C. The reason being a residual central stromal corneal haze post complete healing after graft rejection in 1 (2.85%) case belonging to Group A. Other causes were complete graft failures in 2 (5.71%) cases with one case each belonging to Group B and C resulting in a hazy graft. Lastly it was also noted that 1 (2.85%) case belonging to group B developed graft neovascularisation (Table 9).

The primary goal of our study was to obtain cosmetic and optical results, which was achieved in 28 (80%) cases of the total 35 (100%) cases (Figure 2a and 2b). Of the remaining 7 (20%) cases, visual outcome was not obtained cause of a hazy graft in 4 (11.42%) cases because of residual central stromal corneal haze post graft rejection (Figure 3a), graft failure (Figure 3b) and graft neovascularisation (Figure 3c) and the remaining 3 (8.57%) cases showed clear grafts but optical results were not achieved in these cases due to posterior segment pathologies (Table 10).

## Discussion

Diseases affecting the cornea are a major cause of preventable blindness worldwide [1]. Reconstructive penetrating keratoplasty is often the only surgical alternative in full thickness corneal involvement with diffuse destructive disease of the anterior segment, obscuring the visual axis hence limiting vision sufficiently [2]. These corneal pathologies if involve one or more quadrants of the sclera, require a modified technique of sclerokeratoplasty.

If these corneal pathologies are left untreated, they can progress to significant vision threatening complications [3]. Thus the mainstay of

**Table 5:** Distribution of anterior and posterior synechia cases.

Corneal pathologies	Anterior synechia (In clock hours and degrees)						Posterior synechia	Total
	12 TO 3	3TO 6	6 TO 12	9 TO 12	180 DEGRRE	360 DEGREES		
Group A	0	0	0	0	0	0	3	3
Group B	0	3	3	2	1	0	0	9
Group C	0	1	3	2	0	1	0	6
Total	0	4	6	4	1	1	3	18

**Table 6:** Distribution of cases by the status of lens.

Status of lens	Group A	Group B	Group C	Total
Early cataractous changes	5	3	4	12 (34.28%)
Dense cataract	2	5	3	10 (28.57%)
One quadrant subluxation	0	0	1	1 (2.85%)
Posterior dislocation	0	1	0	1 (2.85%)
Total	7 (20%)	9 (25.71%)	8 (22.85%)	24 (68.57%)

**Table 7:** Intraoperative surgical modifications.

Intraoperative surgical modifications	Group A (n-13)	Group B (n-12)	Group C (n-10)	Total
Cataract extraction with IOL implantation	2	5	2	9 (25.71%)
Cataract extraction with IOL implantation with anterior vitrectomy	0	1	1	2 (5.71%)
Release of anterior/posterior synechia	3	9	6	18 (51.42%)
Pupillary membrane removal	5	7	4	16 (45.71%)
Iris reconstruction	0	4	3	7 (20%)

**Table 8:** Post operative complications.

Post-operative complications	Group A (n-13)	Group B (n-12)	Group C (n-10)	Total
Suture related	1	3	2	6 (17.14%)
Post-operative uveitis	2	2	1	5 (14.28%)
Reformation of synechia	0	2	1	3 (8.57%)
Shallowing of anterior chamber	1	4	3	8 (22.85%)
Early graft rejection	0	3	2	5 (14.28%)

**Table 9:** Distribution of number of cases by visual outcome and graft clarity.

Final best corrected visual outcome	Group A		Group B		Group C		Total
	Clear	Hazy	Clear	Hazy	Clear	Hazy	
HM TO 1/60	0	0	0	1	0	1	2 (57.14%)
2/60 TO 3/60	0	0	0	1	0	0	1 (2.85%)
4/60 TO 5/60	1	1	1	0	1	0	4 (11.42%)
6/60 TO 6/24	6	0	7	0	7	0	20 (57.14%)
6/18 To Above	5	0	2	0	1	0	8 (22.85%)
Total	12	1	10	2	9	1	35
	13		12		10		

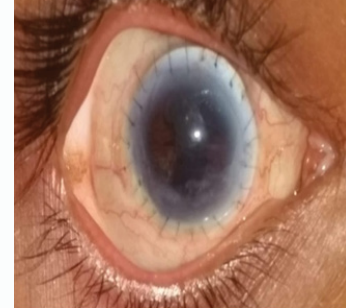**Table 10:** Distribution of cases by the surgical outcome and graft clarity.

Surgical outcome	Group A		Group B		Group C		Total
	Clear	Hazy	Clear	Hazy	Clear	Hazy	
Achieved	11	0	9	0	8	0	28 (80%)
Not achieved	1	1	1	2	1	1	7 (20%)
Total	12	1	10	2	9	1	35
	13		12		10		

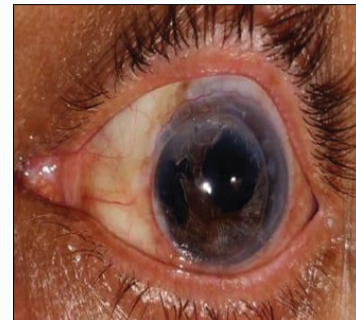
management remains sclerokeratoplasty, a technique first described by Girard in 1956 [4], by which the diseased part of cornea and sclera are removed and replaced with a stronger healthy donor tissue to achieve optimum optical and tectonic results [3].

Our study was undertaken to evaluate the outcome of sclerokeratoplasty exclusively in quiescent healed corneal pathologies. These included full thickness simple corneal opacities, adherent leukomas and anterior staphylomas.

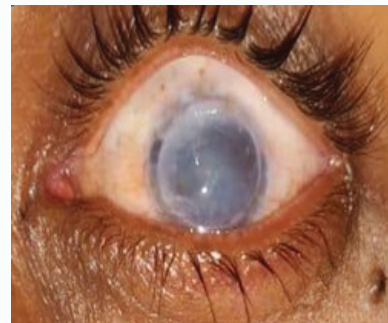In literature, it has been found that only three studies show similarity, two of them being a single case report of acquired staphyloma by Guilherme et al. [5] and by Enrique de la Torre-



**Figure 2a:** Post sclerokeratoplasty clear graft with lens changes, irregular pupil and posterior synechia.



**Figure 2b:** Post sclero keratoplasty clear graft with iris reconstruction and pseudophakia.

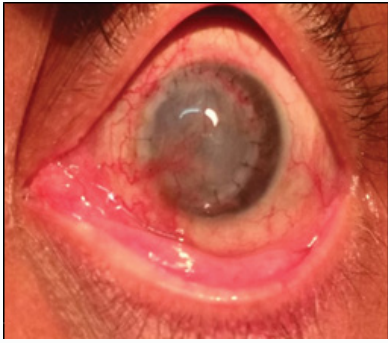


**Figure 3a:** Residual central stromal corneal haze post graft rejection with lens changes.

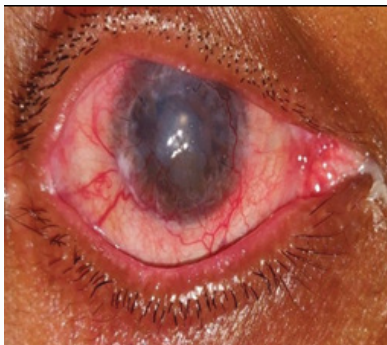
Gonzalez et al. [6] Another study done by Panda et al. [2] compared the results of Penetrating Sclerokeratoplasty (PSKP) with that of Penetrating Keratoplasty in 20 eyes with acquired spherical anterior staphylomas [2].

Unlike our study, Shreya T et al. [7] carried out a study evaluating the outcome of sclerokeratoplasty exclusively in cases with an infective etiology, similarly Panda et al. [2] did a comparative analysis between therapeutic sclerokeratoplasty and therapeutic penetrating keratoplasty in cases of refractory corneal ulcer.

Thus there are many studies in literature related to sclerokeratoplasty either comparing its outcome to penetrating Keratoplasty [2,8] or comparing its different types (lamellar and penetrating) or evaluating its result in cases with a infective etiological



**Figure 3b:** Graft failure.



**Figure 3c:** Graft neovascularisation.

group [7] or in acquired quiescent pathologies [5,6], but none of them were found to be similar to our study, holding it different.

The age group included in our study ranged from 25 to 75 years with a majority of 15 (42.85%) cases accountable between 45 to 55 years of age and an overall male preponderance (57.14%) was as well noted. It was observed that in the case reports by Malta Pio Guilherme et al. [5] and Enrique de la Torre-Gonzalez et al. [6] were conducted similarly on male patients of the age 17 and 23 years respectively.

Of the total a maximum of 14 (40%) grafts were seen to range from 7.5 mm to 9 mm in diameter with a majority among them found to belong to Group A. The other two groups showed a major of their grafts to range between 9 mm to 12 mm.

Similar to our study in the case reports by Guilherme Malta Pio et al. [5] and Malta Pio Guilherme et al. [6] they used grafts of size 8 mm and 7.5 mm respectively. The two studies showed a correlation to our study, as both were performed on cases with acquired anterior staphyloma (quiescent corneal pathologies) treated by sclerokeratoplasty with similarity in graft sizes. Unlike our study the studies done on infective etiologies by Taylor et al. [9] did 35 penetrating, 15 lamellar and just 16 of 35 eyes received a graft sized more than 9.5 mm out of which only 2 had a rim of sclera while Hirst et al. [10] used graft sizes within 11 mm to 14 mm range, of which 10 cases showed the graft size to be 12 mm.

The large corneal grafts required in these cases are associated with a high incidence of graft rejection and glaucoma [11]. Larger grafts may distort the angle anatomy, thus anticipated to have increased chances of secondary glaucoma [3]. If the integrity of the trabecular meshwork, the drainage angle and the canal of Schlemm can be preserved, the incidence of secondary glaucoma can be reduced.

Studies [2] reported no significant association of secondary

glaucoma with sclerokeratoplasty when compared to penetrating keratoplasty. Cobo M used angle supported sutures for preservation of angle anatomy [12].

Burk et al. [13] and Jonas et al. [8] depicted the technique of lamellar preparation of scleral bed for preventing this damage, but in our study recipient corneo-scleral button was obliquely cut to prepare the recipient bed in such way to preserve the angle anatomy and donor graft was prepared in a similar manner as well.

Studies of interest similar to ours as by Enrique de la Torre-Gonzalez et al. [6], where both the donor and recipient tissues were prepared freehand in order to maintain the structure of the recipient angle also it was noted that on the second postoperative day, ocular hypertension developed in one of the patients who was managed by timely medical treatment. Similarly the study by Malta Pio Guilherme et al. [5] did not show any manifestation of post-operative secondary glaucoma. In the study by Panda et al. [2], secondary glaucoma was more associated with eyes that underwent penetrating Keratoplasty as compared to eyes which underwent PSKP showed a lower incidence [2]. In our study all cases were thoroughly evaluated preoperatively and only 3 (8.5%) cases were diagnosed with secondary glaucoma of which 2 (5.71%) cases belonged to Group B and 1 (2.85%) case to Group C, with all cases managed by trabeculectomy.

Development of secondary glaucoma was observed more frequently in studies involving an infective etiology. In the study by Hirst and Lee [10], 13 of 23 patients developed glaucoma from which 6 required surgery, similarly described by Taylor et al. [9]. The study by Shreya et al. [7] showed secondary glaucoma to develop in only 6 (17.6%) patients predominantly in eyes with group A (severe refractory sclerokeratitis) than eyes with group B (corneal perforation) with adjacent scleral involvement and they were successfully managed by trabeculectomy. Hence we can attribute no incidence of secondary glaucoma in our study as with other studies to a detailed preoperative workup with UBM and Gonioscopy aiding to prevent intraoperative complications and postoperative development of glaucoma. Also studies with non-infective or quiescent etiologies similar to ours showed no significant incidence or association with development of secondary glaucoma.

Large grafts are present within close vicinity of limbal vasculature and hence suture related complications are expected to be more common, so are also of prime concern in stimulating graft rejection. If the corneal graft extends to the limbus and beyond the so-called immunological privilege of corneal allografts, which are sutured into a vascular recipient cornea as described by Khoudadoust is lost [14,15].

All our patients required a full-thickness corneal transplantation along with the part of the limbus in the form a sclerokeratoplasty. We therefore accepted the risk of immune suppression in order to increase the graft survival.

In our study it was noted that a large majority of 18 (51.42%) cases showed a two quadrant limbal involvement of which a maximum of 8 (22.85%) cases belonged to Group A. In the other two groups it was found that maximum cases among them had a three quadrant limbal involvement. Unlike our study in the study by ROW Burke et al. [13] done in two patients with an infective corneal pathology and a decompensated keratoglobus, a corneal thinning and destruction of at least 2 o'clock-hours extending beyond the corneoscleral limbus required large grafts. Also a study varying from ours done by Shreya et al. [7] to know the outcome of sclerokeratoplasty in cases

with an infective corneal pathologies showed a two quadrant limbal involvement in a majority of 25 cases. It is noted that the limbal quadrant involvement was not researched much in most of the studies and on correlating our study in quiescent corneal pathologies with that of Shreya et al. [7] in infective corneal pathologies, we can attribute a lesser limbal quadrant involvement with minimal compromise of limbal vasculature in our study to a lower incidence of suture related complications and graft rejections.

Our study showed suture related complications only in 6 (17.14%) cases of which a majority of 3 (8.57%) cases belonged to Group B and all cases were managed with early suture removal. Studies similar to ours on quiescent corneal pathologies, did not show any mention of suture related complications [5,6]. As observed, in the study by Shreya et al. [7] carried out on infective corneal pathologies; suture related complications were observed in 24 (40%) eyes. Panda et al. [2] carried out a study with varied etiologies comparing the results PSKP with that of penetrating keratoplasty and both these studies managed the cases by early suture removal. Also noted in the study by Jonas et al. [8] the frequency of suture loosening and immunological graft rejection was found to be more in eyes with an infective corneal pathology as compared to eyes with an inactive corneal scar with both being managed by sclerokeratoplasty.

Additionally, larger grafts are known to be associated with an elevated incidence of immunological graft rejection. Our study showed early Graft rejection in 5 (14.28%) cases with a majority of 3 (8.57%) cases belonging to Group B and the remaining 2 (5.71%) cases were from Group C. Of the total 5 cases, 4 were managed medically with I/V methyl prednisolone pulse dose of 1 gm per day given for 3 days alongside topical steroids tapered as per patients response. A reversal of graft rejection was seen in 3 (8.57%) cases and graft failure confirmed in 2 (5.71%) cases, of which one case belonged to Group B and C each.

A prospective analysis similar to ours done by Panda et al. [2] in 20 eyes with anterior staphyloma reported a better outcome following PSKP as compared to penetrating keratoplasty during one year follow-up period.

Unlike our study, in the study by Shreya et al. [7] conducted in eyes with infective corneal pathologies, 11 cases landed up in early graft rejection of which a majority of 7 (11.6%) cases belonged to group B, they managed these cases with intravenous methyl prednisolone, out of 11 (18.3%), 5 (10%) graft were saved rest 6 grafts were planned for re- keratoplasty. Also in the study by R O W Burk et al it was seen that although graft failure was prevented in both patients by immune suppression both developed recurrent central epithelial irregularities [16]. Similarly study by Hirst and lee et al. [10] showed that out of the 23 patients, 9 required enucleation or evisceration primarily because of recurrence of the underlying disease process. Among the remaining 14 patients, 2 patients could be defined as having typical rejection episodes with the corneas becoming opaque, while 5 corneas slowly failed without definite reason representing an atypical graft rejection or endothelial failure.

Large corneoscleral grafts may be required in an attempt to salvage the eye, which could otherwise be lost, however the results pertaining to maintenance of graft clarity and vision remain doubtful. The primary goal in our study was to obtain cosmetic and optical results. Out of the total 35 cases, 31 (88.57%) cases showed clear grafts, with a desirable visual outcome obtained in 28 (80%) cases with BCVA 6/60

and above with a similar number of cases found in each group.

A hazy graft was seen in 4 (11.42%) cases with BCVA between HM and 5/60. The reasons associated were, a residual central stromal corneal haze post graft rejection in 1 (2.85%) case belonging to Group A. Other reasons were a complete graft failure in 2 (5.71%) cases with one cases each belonging to Group B and C resulting in a hazy graft. Lastly it was also noted that 1 (2.85%) case belonging to group B developed graft neovascularisation.

A desired Visual outcome was not obtained in 3 (8.71%) cases with clear grafts producing a BCVA between HM and 5/60 with reasons relating to posterior segment pathology such as a macular scar and glaucomatous optic atrophy. Astigmatism, the bugbear of final visual achievement as seen in other studies as an obstacle despite a clear graft, was not encountered in our study.

Studies similar to ours performed on cases with acquired anterior staphylomas showed mixed results such as in a study by Malta Pio Guilherme et al. [5] showed a opacified graft button on postoperative day one with neovascular growth throughout the length with optical results not obtained and vision noted to be hand movement from perception of light in the affected eye on postoperative day 60 after medical intervention. Therefore in this case therapeutic, tectonic and cosmetic requirements were only met. Also in the study by Enrique de la Torre-Gonzalez et al. [6] showed a clear graft with clear improvement in vision from a preoperative perception of light to counting fingers at 2 m distance was only obtained. Unlike our study done in quiescent corneal pathologies, another study done in 1992, Cobo et al. [12] described the use of 14 mm sclerokeratoplasty in five eyes for a variety of diseases [12] with four of these five eyes requiring a further corneal transplant after loss of clarity of the initial graft. Similarly in 1996, Red brake and Buchal described the use of keratoplasty with a scleral rim in the treatment of severe chemical eye burns. Despite all nine eyes being saved, only two of the 9 grafts remained clear [16].

The results in a study by Panda et al done on extensive corneoscleral diseases of different etiology on 166 eyes showed a achievement of graft clarity in about 37% of cases with visual acuity of 6/18 or more in 30%, and above all astigmatism of less than 3D in 64% of eyes all indicating towards the safety of the procedure [2].

Also in the study by Shreya et al done similarly on in 60 eyes with infective pathologies showed BCVA of more than 6/60 in 11 patients (20%) out of which the maximum visual acuity of 6/18 observed in 3 patients (5.45%) with a suboptimal visual recovery of <3/60 seen in overall 28 eyes (50.9 %) [7].

In large grafts, the maintenance of graft clarity and optimal vision still holds mixed results, but on comparing our study to others, we noted that we obtained an optimum number of cases with a clear graft and a good visual acuity, blaming the brunt of a poor visual outcome with clear grafts in our study to posterior segment pathologies. We can attribute our results to a thorough preoperative evaluation with UBM to know the extent of anterior segment destruction helping us make timely reforms and intraoperative modifications. All the above measures credited to the lesser intraoperative complications, suture related problems, development of secondary glaucoma and graft rejection, hence helping us achieve good visual and optical results.

## Conclusion

To summarise, our study was conducted in quiescent corneal

pathologies with a full thickness corneal involvement including a part of the sclera, all patients underwent sclerokeratoplasty to meet the optical results and by priority an attempt to salvage the eye which could be otherwise lost.

Reconstructive procedures with use of large sized corneoscleral grafts involve greater complexity due to loss of limbic support, limbal vascularisation, and distortion of angle structures and thus are associated with higher incidence of intraoperative complications and postoperative problems such as those related to sutures, graft failure, graft rejection and development of secondary glaucoma.

In order to make reforms, it is important to know the extent of anterior segment destruction requiring proper preoperative evaluation. In our study to our advantage we conducted a UBM preoperatively. Hence encountering minimum intraoperative complications and requiring lesser intraoperative modifications. Correlating our study to others, in our study we ensured use of long sutures for good apposition thus reducing the postoperative problems related to sutures. Adding to this, there was also no case of postoperative glaucoma noted. Also incidence of graft rejection reported was low, but cases with graft rejection could be associated with more limbal quadrant involvement, also being primarily responsible for poor graft clarity. Posterior segment pathologies were blamed majorly for poor visual outcome in clear grafts. Thus to briefly summarise in our study most importantly we noted an overall good optimum optical results entailing to good graft clarity and best corrected visual acuity.

## References

- Gupta N, Tandon R, Gupta SK, Sreenivas V, Vashist P. Burden of Corneal Blindness in India. *Indian J Community Med.* 2013;38(4):198-206.
- Panda A, Sharma N, Angra SK, Singh R. Sclerokeratoplasty versus penetrating keratoplasty in anterior staphyloma. *Ophthalmic Surg Lasers.* 1999;30(1):31-6.
- Kocluk Y, Sukgen EA. Results of therapeutic penetrating keratoplasty for bacterial and fungal keratitis. *Int Ophthalmol.* 2016;37(5).
- Girard LJ. Penetrating Sclerokeratoplasty. *Cornea.* 1982;1:45-52.
- Romanian Journal of Ophthalmology. 2019;63(4):379-82.
- de la Torre-Gonzalez E, de León Ascencio CP. Staged penetrating sclerokeratoplasty and penetrating keratoplasty for management of advanced acquired anterior staphyloma. *J Ophthalmic Vis Res.* 2011;6(2):147-50.
- Thatte S, Dube AB, Dubey T, Krishnan M. Outcome of sclerokeratoplasty in devastating sclerocorneal infections. *J Curr Ophthalmol.* 2020;32(1):38-45.
- Jonas JB, Rank RM, Budde WM. Tectonic sclerokeratoplasty and tectonic penetrating keratoplasty as treatment for perforated or predescemetal corneal ulcers. *Am J Ophthalmol.* 2001;132(1):14-8.
- Taylor DM, Stern AL. Reconstructive keratoplasty in the management of conditions leading to corneal destruction. *Ophthalmology.* 1980;87(9):892-904.
- Hirst LW, Lee GA. Corneoscleral transplantation for end stage corneal disease. *Br J Ophthalmol.* 1998;82(11):1276-9.
- Barraquer J. Total penetrating keratoplasty. *Proc R Soc Med.* 1961;54(12):1116-8.
- Cobo M, Ortiz JR, Safran SG. Sclerokeratoplasty with maintenance of the angle. *Am J Ophthalmol.* 1992;113(5):533-7.
- Burk RO, Jousseaume AM. Corneoscleroplasty with maintenance of the angle in two cases of extensive corneoscleral disease. *Eye.* 2000;14(2):196-200.
- Khodadoust AA, Silverstein AM. Studies on the nature of the privilege enjoyed by corneal allografts. *Invest Ophthalmol.* 1972;11(3):137-48.
- Khodadoust AA. The allograft rejection reaction: the leading cause of late failure of clinical allografts. *Ciba Foundation symposium.* 2008;15:151-67.
- Redbrake C, Buchal V. Keratoplastik mit Sklerarung nach schwersten Verätzungen des vorderen Augenabschnittes. *Klin Monatsbl Augenheilkd.* 1996;208:145-51.