

## Case Report

# Platelet-Rich Plasma (PRP) Injections in Rheumatoid Arthritis Knee Joints

Evija Stumbra Stumberga\*

Department of Rheumatology, Riga 1<sup>st</sup> Hospital, Riga, Latvia

## Abstract

Rheumatoid Arthritis (RA) is characterized by dysregulated inflammatory processes in the synovium of the joint. In RA disease course many patients have synovitis in small joints of wrists and feet, along with large joint degenerative disease that manifests or presents with the destruction of both cartilaginous and bony elements of the knee joint. For long-time medication for intra-articular injection therapy included local steroids. New intra-articular treatments options have been proposed by several pain relieve clinics-Platelet-Rich Plasma (PRP). There have been conducted several studies on animals Antigen-Induced Arthritis (AIA) of the large animals injecting PRP in arthritis joints, giving a conclusion that treatment with PRP can alleviate arthritic changes in the synovium and cartilage. However, well depicted human case-control studies have not been yet available for RA patients. Therefore, the present study has been described. The aim of the presented case report was to increase clinical awareness on RA patient knee joint synovitis and possible outcomes of PRP injection.

**Keywords:** Rheumatoid arthritis, Platelet-rich plasma, Knee joint, Intra-articular injections

## Introduction

Rheumatoid arthritis is a chronic systemic autoimmune disease that causes chronic inflammation in joints manifesting with swelling, pain, synovitis and joint destruction [1]. RA affects about over 1.3 million Americans. Women are affected at a younger age than men, more often than men. Onset may be at any age, most often between 30-60 years [1]. RA causes damage mediated by cytokines, chemokines, and metalloproteases. Two cell types are important for the destruction of cartilage and bone. Synovial Fibroblasts (SF) adhere to cartilage and degrade extracellular matrix, but osteoclasts are involved in bone destruction. Both cell types interact with cells of the immune system, maintain the inflammation, producing a large number of cytokines [1]. Moreover, SF in RA patients shows prolonged survival and resistance to apoptosis [1]. Commonly, small joints of the hands (intra-carpal, metacarpophalangeal joints) and feet are coequally involved in the inflammatory process, leading to loss of articular structures. Unfortunately, evidence suggests that up to 40% of people with newly diagnosed RA continue to have active disease one year later because RA treatments are effective, but not to everyone. Higher work disability rates, as well as functional decline, are the causes of the knee and hip joint destruction leading to the total knee and total hip replacement surgery. After 5 years of active disease, approximately 33% of patients are unable to work, and after 10 years, approximately 50% of patients experience substantial functional disability [2]. In daily practice rheumatologists, traumatologists perform intra-articular injections in knee joints trying to reduce joint pain and swelling. The most common treatment is triamcinolone

acetate. Intra-articular triamcinolone acetate injection has long been known as useful local therapy for the management of RA [3]. That performed professionally under Ultrasound guidance have given quick pain relief for RA patients with clinical benefit.

However, many RA patients are afraid of steroid treatment and try to avoid it, preferring other options offered by experienced surgeons. New approaches to reduce the pain and swelling in the arthritis of knees have been proposed by local orthopaedic surgeons. One of them is PRP injections. There are several studies promising new treatment possibilities and better outcomes for pain management in chronic arthritis patients, even RA, proposing that PRP is an ideal treatment [4]. We know that PRP is a blood-derived product containing highly concentrated platelets, and many cell growth factors including transforming growth factor- $\beta$ 1 (TGF- $\beta$ 1), Platelet-Derived Growth Factor (PDGF), Vascular Endothelial Growth Factor (VEGF), and Insulin-Like Growth Factor-I (IGF-1) which promote cell proliferation and differentiation, repairing articular cartilage and removing inflammatory factors in animal studies [5]. In several of the large and small AIA in animal studies, PRP presented inhibition of local inflammatory marker expression; those are responsible for immune system activation already noted in rheumatoid arthritis [6].

The therapeutic efficacy of PRP in these studies demonstrated that treatment with PRP alleviated the chondral and synovial changes seen in AIA.

## Case Presentation

Mr P.N., 45 years old patient was presented to the rheumatology department, Riga 1<sup>st</sup> Hospital, with a 2 weeks history of swelling in both knees, that caused him pain, difficulties to bend his knees, perform daily activities. He was Caucasian, male patient, suffering from long-standing erosive seropositive rheumatoid arthritis for two years. Because of longstanding progressive disease, he has been prescribed Methotrexate (MTX) 15 mg once per week as well as acid folic 5 mg per week. The physical examination was abnormal, tenderness to palpation of both knees, swelling and enlarged joints of both knees as well as calves, Disease Activity Evaluated as DAS 28 score (CRP) Das 28 5.35, Health Assessment Questionnaire (HAQ)

**Citation:** Stumberga ES. Platelet-Rich Plasma (PRP) Injections in Rheumatoid Arthritis Knee Joints. *Ortho*. 2020; 1(1): 1005.

**Copyright:** © 2020 Evija Stumbra Stumberga

**Publisher Name:** Medtext Publications LLC

**Manuscript compiled:** Jan 09<sup>th</sup>, 2020

\***Corresponding author:** Evija Stumbra Stumberga, Department of Rheumatology, Riga 1st Hospital, Riga, Latvia, Tel: 37126108929; Fax: 37126108929; Email: [evijastumbra@inbox.lv](mailto:evijastumbra@inbox.lv)

2,13. The patient admitted that he had performed intra-articular injections in both knees recently, 2 weeks before.

An MRI was performed, for both knee joints 3 months before the PRP injection and radiologists gave the written consent, written below:

Articulatio genu dxt active rheumatoid arthritis with suprapatellar bursitis and synovitis, Baker cyst with hypertrophied synovial tissues. Pes Anserine bursitis. Degenerative changes in Medial Collateral and Anterior Cruciate ligament. Medial meniscus dorsal horn lesion. Widespread degenerative changes in Lateral Meniscus dorsal horn. Marginal erosions in Femur lateral condyle. Femorotibial chondropathy (stage IV). Patellar chondropathy (stage II,III) (Figure 1).

Articulatio genu sin active rheumatoid arthritis with suprapatellar bursitis and synovitis, Baker cyst with hypertrophied synovial tissues. Pes Anserine bursitis. Degenerative changes in Medial Collateral and Anterior Cruciate ligament. Medial meniscus dorsal horn lesion. Femorotibial chondropathy (stage III,IV). Patellar chondropathy (stage III). Initial erosions (Figure 2).

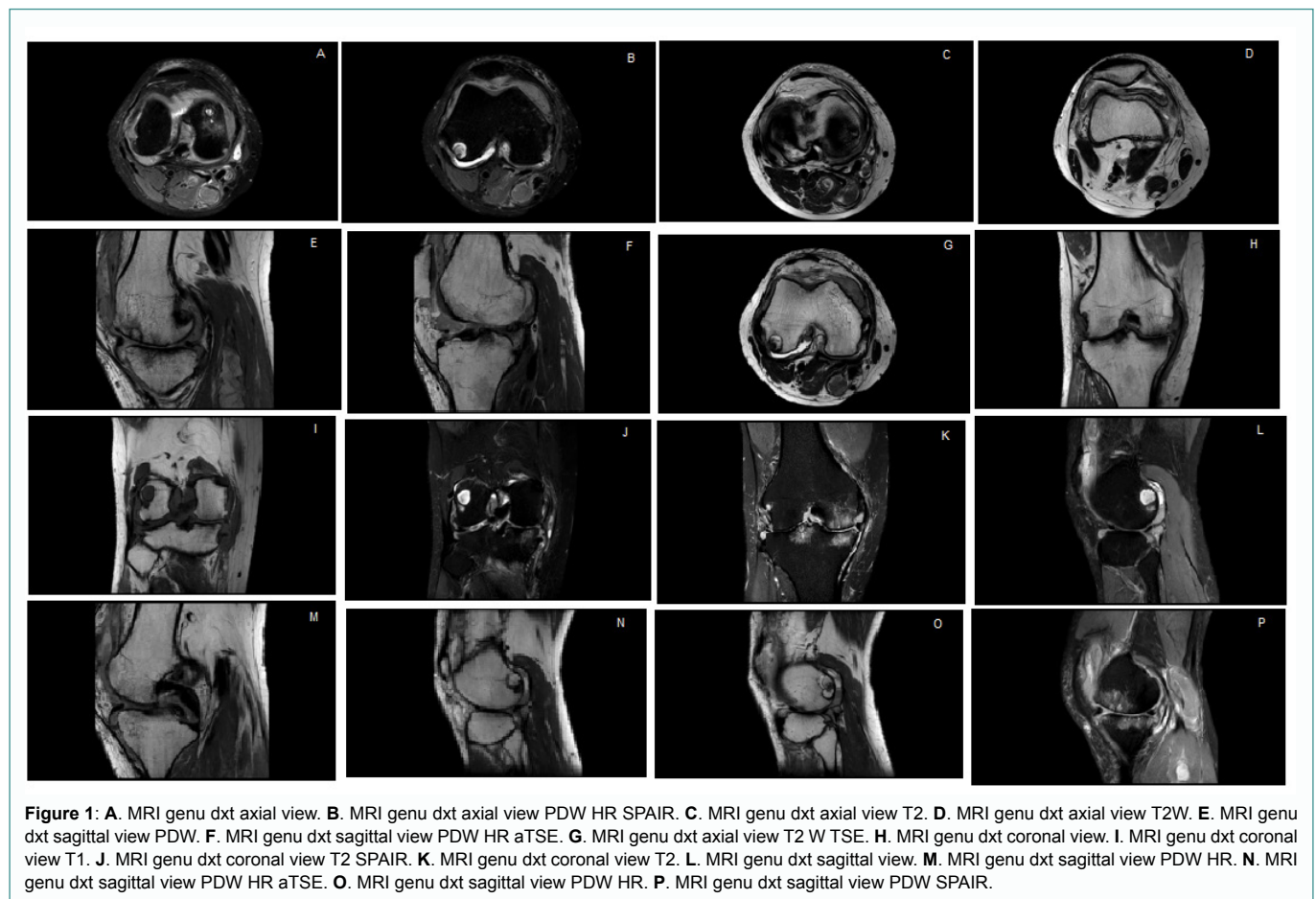
From the MRI images that were done before injection and MRI description above, we can realise the severity of rheumatoid arthritis in this Caucasian, 45 years old male RA patient. Before the PRP injection, other radiological examinations have not been done. After injection, the patient's clinical status did not improve, unfortunately. Knee joints were especially swollen and painful on touch. He had difficulties in walking on the stairs. He used crutches, that he did not use before. He had a severe flare of the disease and his both lower

extremities, calves were swollen and enlarged. Therefore, he admitted to our clinic. Our first differential diagnosis was deep calf vein thrombosis and or septic arthritis. Firstly, we performed blood tests and traumatologist consultation. The blood tests showed D dimers raised, leucocytosis and CRP above normal. Traumatologists asked to perform X-ray on the right knee that was performed. Radiography of the right knee showed tissue swelling of right calf and erosive right knee joint with narrowing of Femorotibial joint space (Figure 3).

Together with angiosurgeons, we performed duplexsonocopy of leg arteries and veins, fortunately, no thrombosis of vessels was found. However, both Baker cysts had been ruptured. Therefore, several aspirations of excess fluid were done to give some relief of pain for the patient. From therapeutic regimes, MTX was raised to 20 mg per week and steroids as methylprednisolone was added 8 mg per day. After a month the blood test was done again, the CRP was normal, but D dimers were still raised, his clinical status had a bit improved. DAS 28 (CRP) 5.01, HAQ 2. Although pain and swelling had decreased a bit he still was using crutches. We are still waiting for a second MRI of both knee joints to evaluate the process remaining in his knee joints.

## Discussion

Despite suggestions that PRP may be an effective therapeutic agent for RA little is known about the possible outcomes of PRP injections in large joints (knees and hips) over the course of the RA disease. Platelet Rich Plasma (PRP) is a simple, low-cost and minimally invasive method that has been widely used and advised to treat different origin knee pathology, but can it be applicable for RA patients?



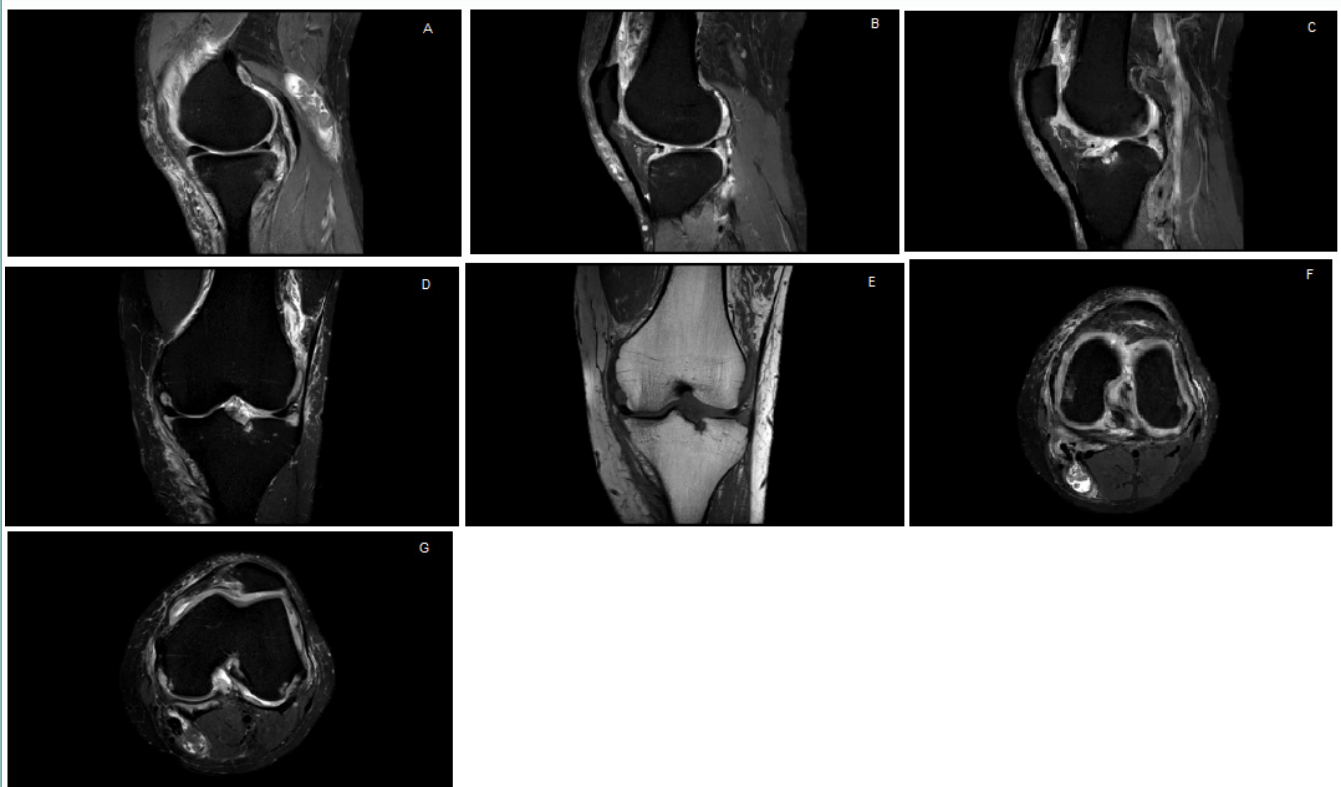


Figure 2 : MRI genu sin.

A. MRI genu sinsagittal view. B. MRI genu sin sagittal view PD. C. MRI genu sin sagittal view PDW SPAIR. D. MRI genu sin coronal view T2. E. MRI genu sin coronal view T1. F. MRI genu sin axial view.png PDW HR SPAIR. G. MRI genu sin axial view.



Figure 3: X-ray of the right knee.

A. Anteroposterior X-ray of the knee joint. B. Lateral X-ray of the knee joint.

After several experimental studies, PRP [4,5], has been suggested as an effective additional therapeutic regime for RA patients, improving damaged tissue regeneration, by promoting new vessel formation as well as delivering Vascular Endothelial Growth Factor (VEGF) release, that helps in new blood vessel formation, thereby increasing vascularity in injured areas. In inflammatory arthritis like RA, neovascularisation is already present together with synovial hyperplasia. This is well observed in musculoskeletal ultrasound of joints of RA patients. Therefore, this could be quite risky (hazardous) for real RA patients with uncertain outcomes, possibly involving a more aggressive course of the disease. What is more, migration and invasion of synovial fibroblasts in patients with RA that are already

characterised with resistance to apoptosis and extended survival might involve new and new joints unaffected by RA destructive process that might cause new unfavorable exacerbations of RA?

### Conclusion

The aim of sports medicine performing clinical interventions is to gain rapid tissue repair and enhance healing, in the shortest possible time to restore functional level While in RA patients PRP injections in knee joints may promote exacerbation of joint swelling, synovitis and may even trigger present Baker Cyst rupture that mimics deep vein thrombosis of calf veins. Therefore, the use of PRP for RA patients may be quite challenging treatment and it asks for more experience and evidence for consideration of this treatment.

---

## References

1. Burmester GR, Pratt AG, Scherer HU, Van Laar JM. Rheumatoid arthritis: pathogenesis and clinical features. In: Bijlsma JWJ, editors. *EULAR Textbook on Rheumatic Diseases*, 1st ed. London: BMJ/ EULAR; 2012. p. 206-31.
2. Atzinger CB, Guo JJ. Biologic Disease-Modifying Antirheumatic Drugs in a National, Privately Insured Population: Utilization, Expenditures, and Price Trends. *Am Health Drug Benefits*. 2017;10(1):27-36.
3. Scherer J, Rainsford KD, Kean CA, Kean WF. Pharmacology of intra-articular triamcinolone. *Inflammopharmacology*. 2014;22(4):201-17.
4. Tong S, Zhang C, Liu J. Platelet-rich plasma exhibits beneficial effects for rheumatoid arthritis mice by suppressing inflammatory factors. *Mol Med Rep*. 2017;16(4):4082-8.
5. Yan S, Yang B, Shang C, Ma Z, Tang Z, Liu G, et al. Platelet-rich plasma promotes the migration and invasion of synovial fibroblasts in patients with rheumatoid arthritis. *Mol Med Rep*. 2016;14(3):2269-75.
6. Lippross S, Moeller B, Haas H, Tohidnezhad M, Steubesand N, Wruck CJ, et al. Intraarticular injection of platelet-rich plasma reduces inflammation in a pig model of rheumatoid arthritis of the knee joint. *Arthritis Rheum*. 2011;63(11):3344-53.