

Case Report

Recurrent Vesical Calculus Formation Leading to Spontaneous Vesicovaginal Fistula in A Young Girl

Vishwajeet Singh^{1*}, Mohit Pandey² and Gyanendra Singh¹

¹Department of Urology, King George's Medical University, India

²Department of Radio-Diagnosis, TS Misra Medical College and Hospital, India

Abstract

Vesical calculi are common in pediatric population especially in the Indian subcontinent. Spontaneous vesicovaginal fistula formation as a complication of long standing recurrent vesical calculus in a young girl has seldom been reported in the literature. We hereby report a case of 15 year young girl who had a history of recurrent, impacted vesical calculus disease. She now presented with complaint of continuous urinary leakage per vaginum for last 6 years. Transurethral holmium laser lithotripsy was done to make her stone free. The chemical stone analysis revealed predominantly of ammonium urate stone Transvaginal repair of vesicovaginal fistula with interposition of Martius flap was done 6 weeks following cystolithotripsy. The patient is dry following repair and doing well in 12 months follow-up.

Keywords: Vesicovaginal fistula; Vesical calculi; Recurrent; Urinary leak

Introduction

Vesical calculus disease is common in paediatric population especially in India [1]. Long-standing large vesical calculus can lead to pressure necrosis and erosion of the bladder wall leading to vesico-vaginal fistula. Vesical calculus disease leading to spontaneous vesicovaginal fistula in a child has seldom been reported in the literature [2-4]. We herein report a case of spontaneous vesicovaginal fistula formation after vesical calculus disease in a young girl.

Case Presentation

A 15 year young girl presented to our hospital with complaint of continuous urinary leak per vaginum for last 6 years. She had history of recurrent vesical calculi for which she underwent open suprapubic cystolithotomy twice in 2011 and again in 2013 at a community health centre. The patient was never followed-up at community health center following second open cystolithotomy procedure. In the year 2015 she started to have irritative voiding symptoms for which her parents never consulted to physician. Later on she developed urinary leak per vaginum. She was seen by a local practitioner and then referred to our center. On examination, she was well developed for her age. Her abdominal examination showed a suprapubic midline scar of previous open cystolithotomy. On vaginal examination she had urinary leak and a defect was felt on the anterior vaginal wall which could admit little finger easily. The tip of finger could feel a hard stone.

On cystoscopic examination under anesthesia an impacted trigonal bladder stone (3 cm × 2 cm) was present which was

fragmented by Holmium Laser lithotripsy. After removal of all stone fragments a large fistulous opening (2 cm × 2 cm) was seen in the trigonal region of the bladder which was seen communicating with vagina (Figure 1). Rest of the bladder appeared normal. Later on CT urography, both kidneys and ureters had a normal outline and function and contrast was seen leaking into the vaginal cavity through the fistula between urinary bladder and vagina (Figure 2). Urinalysis was unremarkable and urine culture was sterile. The chemical stone analysis showed predominantly ammonium urate stone.

The patient underwent transvaginal repair of vesico-vaginal fistula 6 weeks following cystolithotripsy. A limited right lateral episiotomy and Martius flap interposition was done. An indwelling urethral catheter and a suprapubic catheter were used for post-operative drainage of the bladder. The patient made an uneventful recovery and was discharged after 3 weeks following removal of the catheters. The patient is voiding well and cured of urinary incontinence. She is doing well in last 12 months follow-up. Her follow-up ultrasound of Kidney, Ureter and Bladder (KUB) showed normal study with negligible post void residue.

Discussion

Vesical calculus disease in paediatric population is endemic in various parts of India [1]. It is also known that long standing vesical

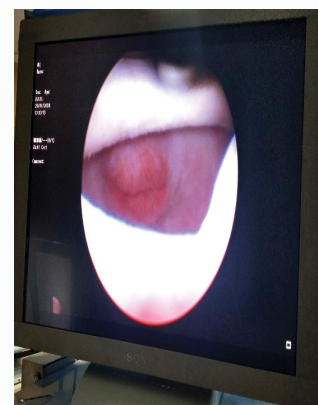


Figure 1: Cystoscopic view of the vesicovaginal fistula.

Citation: Singh V, Pandey M, Singh G. Recurrent Vesical Calculus Formation Leading to Spontaneous Vesicovaginal Fistula in A Young Girl. *Ann Clin Case Stud.* 2022; 4(3): 1059.

Copyright: © 2022 Vishwajeet Singh

Publisher Name: Medtext Publications LLC

Manuscript compiled: Sep 19th, 2022

***Corresponding author:** Vishwajeet Singh, Department of Urology, King George's Medical University, Chowk, Lucknow, Uttar Pradesh, India, 226003, Tel: +91-760768354; E-mail: drvishwajeet68@gmail.com

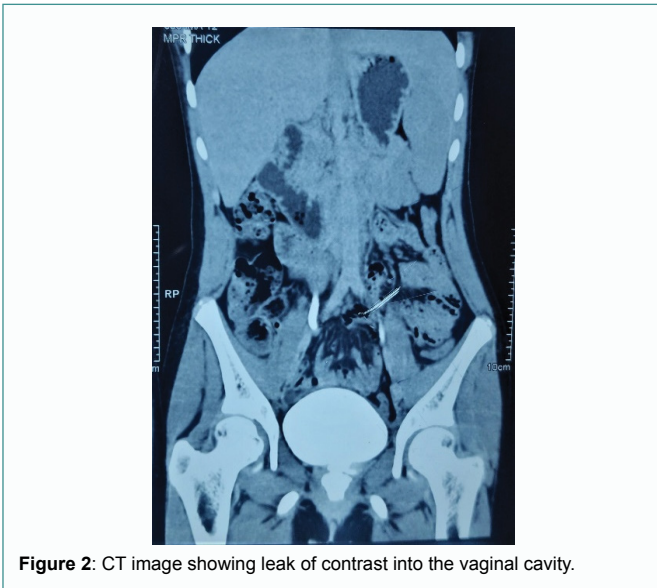


Figure 2: CT image showing leak of contrast into the vaginal cavity.

calculus can even erode through the bladder wall [2]. In spite of high incidence of vesical calculi, spontaneous vesicovaginal fistula formation as a complication is rare and even rarer in the paediatric population [2,3]. Vesical calculi are common associated finding in long standing cases of vesicovaginal fistula. Women with vesicovaginal fistula limit their fluid intake for fear of constant urinary leakage which predisposes them to stone formation [3]. Vesical calculus has been mentioned as one of the lesions complicating a vesicovaginal fistula. It can further erode through the anterior and posterior vaginal wall leading to a complex vesicovaginal and rectovaginal fistula [3-6]. Vesical calculus has been reported as one of the causes of recurrences of vesicovaginal fistula. The previous intravesical suture may act as a nidus for stone formation. The stone prevents the healing of the mucosa of the bladder and eroded through the bladder wall causing the recurrence of vesicovaginal fistula [7]. Primary vesical calculus in paediatric population leading to spontaneous vesicovaginal fistula formation is very rare [2,3,4,8]. In our patient, the possible mechanism of fistula formation could have been the recurrent and neglected vesical calculus became impacted and then eroded the posterior bladder wall led to the communication with vaginal lumen. She developed urinary symptoms and later on urinary leak per vaginum 6 years after second open suprapubic cystolithotomy. Once the fistula occurs, repair should be undertaken after resolving stone-induced edema and friability of the vesical wall [9]. In our case we performed staged procedure. In first stage transurethral holmium laser lithotripsy was done and 6 weeks later transvaginal fistula repair was done. The chemical analysis of stone revealed predominantly ammonium urate stone consistent with endemic stone diseases in pediatric population [10,11]. The patient should be followed regularly to prevent any stone recurrence and or adverse events in future.

Declarations

Consent to participate

The Written Consent of participation was taken from the patient for publishing a case report.

Consent for publication

The authors give the right to publication for SN comprehensive clinical Medicine.

Author's contribution

Author: Substantial contributions to the conception or design of the work and the acquisition. Drafting the work or revising it critically for important intellectual content. Co-Author: Agreement to be accountable for all aspects of the work.

References

1. Bakane BC, Nagtilak SB, Patil B. Urolithiasis: A tribal Scenario. *Indian J Pediatr.* 1999;66(6):863-5.
2. Mukerji AC, Ghosh BC, Sharma MM, Taneja OP. Spontaneous urinary fistula caused by vesical calculus. *Br J Urol.* 1970;42(2):208-12.
3. Singh K. An unusual complication of vesical stones. *Int Urogynecol J Pelvic Floor Dysfunct.* 2002;13(1):50-1.
4. Moir JC. Vesicovaginal fistula: thoughts on the treatment of 350 cases. *Proc R Soc Med.* 1966;59(10):1019-22.
5. Counsellor VS, Haigler FH Jr. Management of urinary vaginal fistula in 253 cases. *Am J Obstet Gynecol.* 1956;72(2):367-76.
6. Dalela D, Goel A, Shakhwar SN, Singh KM. Vesical calculi with unrepaired vesicovaginal fistula: a clinical appraisal of an uncommon association. *J Urol.* 2003;170(6 Pt 1):2206-8.
7. Chien WH, Liang CC. Iatrogenic bladder stone and associated vesicovaginal fistula after hysterectomy. *Gynecologic Surg.* 2006;3(2):134-5.
8. Lavery DW. Vesico-vaginal fistulae; a report on the vaginal repair of 160 cases. *J Obstet Gynaecol Br Emp.* 1955;62(4):530-9.
9. Mahapatra TP, Rao MS, Rao K, Sharma SK, Vaidyanathan S. Vesical calculi associated with vesicovaginal fistulas: management considerations. *J Urol.* 1986;136(1):94-5.
10. Michell AR. Urolithiasis-historical, comparative and pathophysiological aspects: a review. *J R Soc Med.* 1989;82(11):669-72.
11. Ellis H. A history of bladder stone. *J R Soc Med.* 1979;72:248-51.