

Review Article

Singular Cause of the Air Bubbles of Roustons

Ickamba Houchi A*, Bizimana Darbi J, El Fenni and Zamani O

Department of Radiology, Mohamed V Military Instruction Hospital, Mohamed V University, Morocco

Abstract

The rarity of the Fournier's gangrene is known to the scientific community, especially when it is of iatrogenic traumatic origin. This is a 56-year-old man, with no particular history, admitted to the emergency room of the Mohamed V military instruction hospital in Rabat in January 2020 for taking charge of Fournier's gangrene probably post-traumatic origin after accidental ablation of a bladder sounding. Imaging is of great importance for the diagnostic orientation and the assessment of lesions.

The patient will benefit from medical urological management (tetanus serotherapy, antibiotic therapy, analgesic, correction of hydroelectrolytic disorders) and surgical (debridement with hyperbaric oxygen therapy and compression bandage). The evolution was favorable. The peculiarity of this observation lies in its iatrogenic etiology. The objective of this work is to recall the interest of imaging in the diagnostic orientation of Fournier's gangrene.

Keywords: Fournier's gangrene; Iatrogenic trauma; Imagery

Introduction

Fournier's gangrene has aroused little definitive consensus on its definition in the scientific community since its first description in 1764 [1]. This controversy forces many authors to favor the formulation of idiopathic gangrene of the external genital organs which is characterized by an insidious installation (sometimes simple pruritus or pain at the level of the EMBs) often lead to a delay in the diagnosis and can be encountered whatever age [1]. It is a rare condition that affects several regions of the world and is found in 0.02% of urology patients. The microbial flora is mixed and varied in relation to a particular gateway. The disease often progresses in 2 phases, a phase of invasion (edema, erythema in the external genital organs) [2] and a phase of deterioration of the general condition (blackish patches of necrosis, severe infectious syndrome) which can be fatal by septic shock.

The imaging, including ultrasound and computed tomography, necessary for the diagnosis and inventory of loco-regional and distant lesions. Therapeutic care combines the triad of medical, surgical and complementary treatment. The aim of this study is to describe the rarity of the iatrogenic traumatic origin in the occurrence of this pathology and to demonstrate the value of imaging in the positive diagnosis of Fournier's gangrene.

Patient and Observation

This is a 56-year-old man, with no particular history, who reports a consultation in a private practice for pelvic pain accompanied by analgesic treatment a few days before his admission to the emergency

Citation: Ickamba Houchi A, Bizimana Darbi J, El Fenni, Zamani O. Singular Cause of the Air Bubbles of Roustons. Open J Clin Case Rep. 2020;1(1):1002.

Copyright: © 2020 Ickamba Houchi A

Publisher Name: Medtext Publications LLC

Manuscript compiled: Nov 23rd, 2020

***Corresponding author:** Aaron Ickamba Houchi, Department of Radiology, CHU IBN SINA, Mohamed V University of Rabat-Morocco, 25 Rue Siam Avenue Madagascar, Dior Jama, Building B Sanaobar, Apartment 2, First Floor, 10000, Rabat, Morocco, Tel: + 212636451981; Email: aaronherbert2020@gmail.com

room of the military instruction hospital. Mohamed V of Rabat because of the persistent symptoms, the patient returns home with a bladder catheterization. Faced with the accidental withdrawal of the bladder catheter after three days and in front of the exasperation of the pains, he returned to the emergency room. The clinical examination reported a relatively good general condition, a fever, a red left bursa with exacerbated pain when walking.

The ultrasound indicated for suspicion of a collection shows hyperechoic intra scrotal images with infiltration of soft tissues and collection of average abundance on the right. The bursae are intra scrotal, homogeneous without parenchymal anomalies. The pelvic CT supplement confirms the hydro-aeric levels with scrotal, perineal and abdominal extension, suspecting Fournier's gangrene probably after traumatic bladder probing. The patient will benefit from urological management through the admission of tetanus serotherapy, triple antibiotic therapy combining analgesics, antipyretics and correction of hydroelectrolyte disorders. Surgical management by debridement after stabilization of the hemodynamic state (fluid electrolyte rebalancing) carried out in the operating room under general anesthesia with hyperbaric oxygen therapy and compression dressing twice a day. The outcome was favorable, given the clinical improvement, the patient returned home after 14 days of hospitalization.

Discussion

It was in 1764 that Baurienne made the first description of Fournier's gangrene, but it was the French dermatologist Jean-Alfred Fournier [1] who gave his name to the disease after its description in 1883 on cases of scrotal gangrene occurring in young men.

The true incidence of the disease is not well known. It is a rare condition which affects all regions of the world and is found in 0.02% of urology patients. Although the age of patients varies between 30 and 60 years, there is preponderance in the increasingly elderly male population. Women are less affected and in this specific case the starting point of the condition is often gynecological [3].

Infection of the skin and subcutaneous tissue develops from a gateway to follow the anatomical paths delimited by the fascia, it progresses rapidly (3 cm/hr - 4 cm/hr). Histological analysis in fact found necrosis of the fascia, a leukocyte and bacterial infiltrate extended to the deep dermis and necrosis of the vessels [4].

But overall we describe 3 starting points: cutaneous (acute and chronic skin infections of the scrotum and balanitis), anorectal. (Peri-rectal and perianal abscesses) and urological (strictures of the urethra, peri-urethral instrumentation in particular indwelling catheters) while signifying that this portal of entry is difficult to identify when the lesions are too extensive [5]. Rectal instrumentations, colonic perforations secondary to cancer, diverticulosis and hemorrhoid cures are the entry points described in the literature. The spread of the infection then takes place according to the anatomical distribution spaces.

There are many contributing causes. Mainly hygienic conditions, age, alcoholism, immunity, diabetes, malnutrition, morbid obesity, corticosteroid therapy, viral infections (HIV), blood diseases, cancers, pelvic vascular pathologies, neurological damage to the marrow with decreased perineal sensitivity [6]. For some authors, the bacterial flora generally depends on the site of origin and the germs involved, gram-negative anaerobes predominate in rectal etiologies and gram-positive aerobes in urethral etiologies. The iatrogenic urological traumatic origin is the most likely for our observation, but in reality, very little publication on this etiology because of the growing mistrust of medical acts with judicial councils by many patients.

The clinical presentation is sometimes atypical at the beginning, the clinician should look for symptoms, a recent history of perineal trauma, ureteral stenosis, scrotal infection etc. partly explaining the average diagnostic time that remains extended, six days on average. The clinical diagnosis only becomes evident when edema, crepitations, areas of dark red color which rapidly progress to extensive gangrene appear, especially when they associate signs of severe sepsis. In a recent article [2,7], a diagnostic score based on CRP, leukocytosis, hemoglobin, sodium, creatinine and glucose is mentioned. This LRINEC (Laboratory Risk Indicator for Necrotizing Fasciitis) score would make it possible to suspect necrotizing fasciitis despite the insufficiency of local signs.

Although the diagnosis of Fournier's gangrene is clinical, medical imaging plays a major role in the early diagnosis and workup of the lesions. Conventional radiography may indicate the presence of air in the subcutaneous tissue before the onset of crepitations on physical examination [2,8]. Ultrasound (Figure 1) is a simple, fast and accessible examination, it can objectify a skin thickening of the scrotum, possibly of the intrascrotal fluid and especially a dissemination of characteristic gas bubbles in the form of hyperechoic islands [9,10]. It also helps rule out other diagnoses such as strangulated inguinal hernia, testicular torsion or orchio-epididymitis. Pelvic computed tomography (Figure 2a) occupies a prominent place [11], more specific, it reveals the presence and extension of subcutaneous gas (Figure 2b and c), specifies the extent of the lesions and often shows the starting point of the process: abscess or tumor of the pelvic, digestive, or urogenital organs, which will guide the surgeon in his intervention. But when possible, the investigations can be pushed by the realization of other means of imaging such as scrotal MRI [5]. However, imaging should never delay surgical management.

The differential diagnosis between Fournier's gangrene and non-necrotizing bacterial dermo-hypodermis is often difficult. The initial signs are often identical (pain, redness, edema). But the major systemic signs disproportionate to the local signs, even very limited skin necrosis, a grayish appearance and foul odor of the skin are key elements rather in favor of Fournier's gangrene.

Therapeutic care combines the triad of medical, surgical and complementary treatment. Medical treatment with an initial adjuvant and probabilistic triple antibiotic therapy is initiated by the intravenous route as quickly as possible, before the block and as soon as the bacteriological samples have been taken, associated with analgesics, antipyretics and control of hydro electrolytic disorders [12]. The key word of surgical treatment is speed after stabilization of the hemodynamic state; it must be aggressive with debridement to macroscopically healthy tissue, lavage, drainage, necrosectomy, total

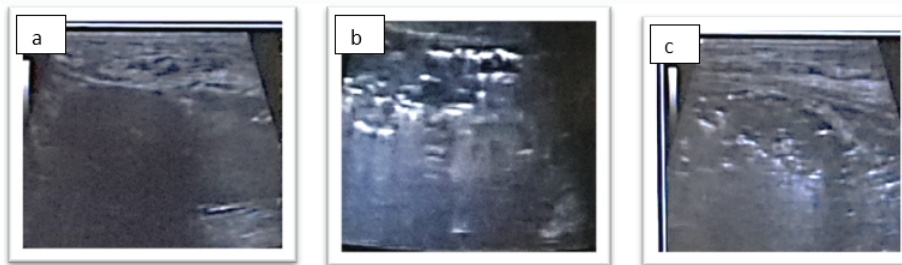


Figure 1: Hyperechoic intra scrotal ultrasound images predominantly on the left. The testes are intra scrotally, homogeneous without parenchymal anomaly. There is an infiltration of the soft parts with a collection of medium abundance especially on the right.

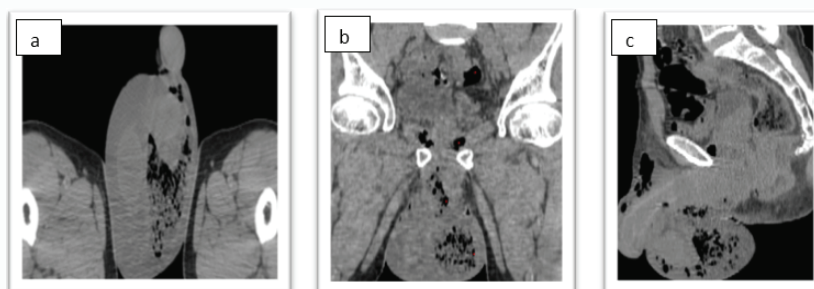


Figure 2: Axial, coronal and sagittal pelvic CT images without injection of iodinated contrast product, revealing intra scrotal, perineal and abdomino-pelvic hydro-aeric levels in favor of Fournier's gangrene.

excision of lesions and exploration of the portal of entry. Suprapubic urinary drainage is recommended in extensive gangrene. Colostomy should be systematically discussed because it is essential in the event of serious disrepair [13].

Complementary treatments are essentially nutrient resuscitation and hyperbaric oxygen therapy which remains to be discussed on a case-by-case basis because of the controversy related to its efficacy or not in Fournier's gangrene [14].

Conclusion

Fournier's gangrene is a serious condition that requires rapid assessment of the degree of urgency with imaging. Scrotal ultrasound, preferably coupled with Doppler, is an excellent diagnostic imaging technique. But CT is essential for the assessment of locoregional and remote extension. MRI is reserved for occasional cases for which other imaging methods have not been conclusive. Medical and surgical management must be early and multidisciplinary in order to prevent the fatal complications inherent in this pathology.

Conflicts of Interest

The authors declare no conflict of interest and no grant for this work.

References

1. Fournier JA. Gangrène foudroyante de la verge. *Med Prat.* 1883;4:589-97.
2. Biyani CS, Mayor PE, Powell CS. Case report: Fournier's gangrene - roentnographic and sonographic findings. *Clin Radiol.* 1995;50:728-9.
3. Eke N. Fournier's gangrene: a review of 1726 cases. *Br J Surg.* 2000;87(6):718-28.
4. Jones RB, Hirschmann JV, Brown GS, Tremann JA. Fournier's syndrome: necrotizing subcutaneous infection of the male genitalia. *J Urol.* 1979;122(3):279-82.
5. URO'ANDRO - Volume 1 - N° 2 - Avril 2014
6. Norton KS, Johnson LW, Perry T, Katina Perry H, James Sehon K, Gazi Zibari B. Management of Fournier's gangrene: an eleven-year retrospective analysis of early recognition, diagnosis, and treatment. *Am Surg.* 2002;68(8):709-13.
7. Wong CH, Khin LW, Heng KS, Kok-Chai Tan, Cheng-Ooi Low. The LRINEC (Laboratory Risk Indicator for Necrotizing Fasciitis) score: A tool for distinguishing necrotizing fasciitis from other soft tissue infections. *Crit Care Med.* 2004;32(7):1535-41.
8. Fisher JR, Conway MJ, Takeshita RT, Sandoval MR. Necrotizing fasciitis. Importance of roentgenographic studies for soft-tissue gas. *JAMA.* 1979;241(8):803-6.
9. Morrison D, Blaivas M, Lyon M. Emergency diagnosis of Fournier's gangrene with bedside ultrasound. *Am J Emerg Med.* 2005;23(4):544-7.
10. Yen ZC, Wang HP, Ma HM, Shyr-Chyr C, Wen-Jone C. Ultrasonographic screening of clinically suspected necrotizing fasciitis. *Acad Emerg Med.* 2002;9(12):1448-51.
11. Guibal F, Muffat-Joly M, Terris B. et al. Necrotizing fasciitis. *Lancet.* 1994;344:1771.
12. Bédos JP. Necrotising cutaneous infections and necrotizing fasciites: what antibiotic agents to use and how? *Ann Fr Anesth Reanim.* 2006;25(9):982-5.
13. Bronder CS, Cowey A, Hill J. Delayed stoma formation in Fournier's gangrene. *Colorectal Dis.* 2004;6(6):518-20.
14. Mindrup SR, Kealey GP, Fallon B. Hyperbaric oxygen for the treatment of Fournier's gangrene. *J Urol.* 2005;173(6):1975-7.