

Case Report

Spontaneous Lumbar Artery Rupture in a Child after Renal Transplantation

Rancan A^{1,2}, Garcia Magne M^{1,2}, Battistel M³, Parolin M¹, Barbiero G³, Gamba P^{1,2} and De Corti F^{1*}

¹Department of Women's and Children's Health, Padua University Hospital, Italy

²University of Padua, Italy

³Padua University Hospital, Italy

Abstract

Background and aim: Spontaneous Lumbar Artery Rupture (LAR) is a rare event that seems particularly associated with old age, renal failure requiring dialysis, anti-coagulant treatment and iatrogenic or accidental trauma. Only one case has been reported after renal transplantation. The aim of this study is to present the first reported case of LAR in children.

Case presentation: An 8-months old boy was referred to our Center for end-stage renal disease secondary to posterior urethral valves. Pre-emptive kidney transplantation was suggested. Transplantation was performed at 11-months of life, complex bench surgery was required. Acute venous thrombosis occurred, and, despite prompt surgical and medical treatment, the graft was lost and removed. The following evolution was regular, and the boy was discharged with subcutaneous heparin therapy. Thirteen days after surgery he presented for rapidly growing abdominal mass and the signs of hemorrhagic shock. A contrast-enhanced CT was performed, showing a large retroperitoneal hematoma with active leakage. Urgent angiography was performed, revealing extravasation from the 3rd right LA and ultra-selective embolization was successfully performed. After stabilization, the patient underwent surgical drainage of the hematoma. Post-operative evolution and follow-up were regular.

Conclusion: Spontaneous lumbar artery rupture is a rare event, even in the adult. Impaired renal function and anticoagulation therapy in association with a recent story of renal transplantation might represent important risk factor, especially for younger patients. Immediate identification and appropriate intervention are mandatory.

Keywords: Lumbar artery; Rupture; Renal transplantation; Children

Abbreviations

LAR: Lumbar Artery Rupture; ESRD: End Stage Renal Disease; PUV: Posterior Urethral Valves; POD: Post Operative Day; LA: Lumbar Artery; LMWH: Low Molecular Weight Heparin

Introduction

Spontaneous lumbar artery rupture is a rare cause of retroperitoneal hematoma in the adult population. No pediatric case has been previously reported, to date. Here we present the first case of spontaneous lumbar artery rupture (LAR) in children.

Case Presentation

An 8-months old boy was referred to our Center for End-Stage Renal Disease (ESRD) secondary to Posterior Urethral Valves (PUV). Severe PUV were diagnosed antenatally and treated in utero in another Center. Despite the best ante- and post-natal management, he underwent ESRD and pre-emptive kidney transplantation was indicated. Since the right kidney showed renal cystic dysplasia and was functionally excluded at scintigraphy, right nephrectomy was

performed at 8 months old. Renal transplantation was performed at 11-months of life, the patient weighting 7.6 kg, Schwartz's GFR 8.2 ml/min/1.73 m², body weight ratio Recipient: Donor=1:3. Given patient's small weight and altered coagulation tests, introduction of continuous heparin infusion was assessed preoperatively. The extraperitoneal approach was adopted and the graft located in the right lumbar fossa. Complex bench surgery was required due to the presence of two arteries and two veins in the donor kidney. Donor arterial patch was anastomosed to recipient Aorta, venous patch to Inferior Vena Cava and the ureter to bladder with the Lich-Gregoir technique. Unfortunately, acute venous thrombosis occurred right after declamping and, despite immediate surgical revision and administration of intravenous heparin and local thrombolytics, the graft was lost and removed in the first Postoperative Day (POD). The following evolution was regular, and the boy was discharged on 12th POD with subcutaneous Low Molecular Weight Heparin (LMWH) therapy. Dialysis was never required. The morning after, at 13th POD, he returned to our Emergency Department because of a rapidly growing right abdominal mass, lethargy, vomiting and flank pain. He presented tachypnea (respiratory rate 50 bpm), tachycardia (heart rate 185 bpm), and hypotension (arterial pressure 68 mmHg/51 mmHg). Serum hemoglobin was at 3.6 g/dL. In front of a rapidly evolving hemorrhagic shock of undetermined origin, fluid resuscitation was promptly carried out, the child sedated and intubated, and a central venous catheter for possible hemodialysis (Quinton) put in place. A contrast-enhanced CT was then performed, showing a large retroperitoneal hematoma with active arterial leakage (Figure 1). Urgent angiography was performed, revealing extravasation from the 3rd right Lumbar Artery (LA), and ultra-selective embolization was performed. Both embolization particles and a spiral were used.

Citation: Rancan A, Garcia Magne M, Battistel M, Parolin M, Barbiero G, Gamba P, et al. Spontaneous Lumbar Artery Rupture in a Child after Renal Transplantation. *Ann Clin Case Stud.* 2022; 4(4): 1063.

Copyright: © 2022 Rancan A

Publisher Name: Medtext Publications LLC

Manuscript compiled: Nov 18th, 2022

***Corresponding author:** Federica De Corti, Pediatric Surgery Unit, Department of Women's and Children's Health, Padua University Hospital, Padua, Italy; E-mail: federica.decorti@aopd.veneto.it

After stabilization, the patient underwent surgical drainage of the hematoma. The LA was identified and further ligated. No aspect of aneurysm was found. Post-operative evolution was satisfactory. Hemoglobin level stabilized. Only one dialysis session was performed, to washout the contrast medium. Renal function then stabilized around 600 $\mu\text{mol/L}$, which was patient's pre-operative value. Follow-up Doppler ultrasound at 12th POD showed normal venous and arterial flux, thus heparin therapy was discontinued and replaced by antiplatelet therapy *via* acetylsalicylic acid.

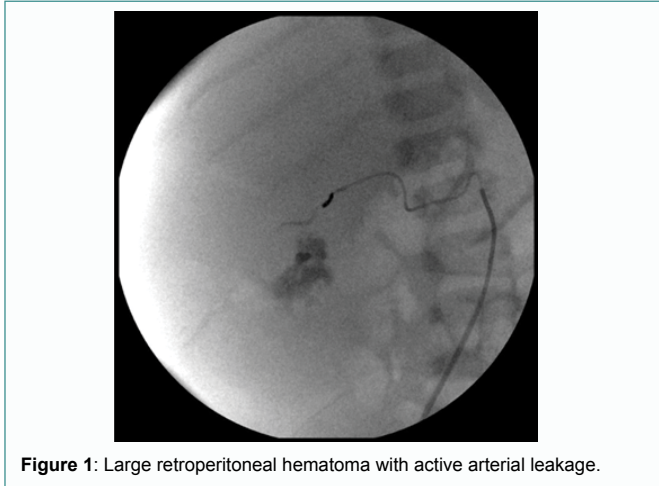


Figure 1: Large retroperitoneal hematoma with active arterial leakage.

Discussion

Retroperitoneal hemorrhage is characterized by sudden onset of bleeding in the retroperitoneal space. Clinically, it manifests as progressive abdominal pain that rapidly evolve to palpable abdominal mass and hypotension that can result in abdominal compartmental syndrome, hemorrhagic shock and eventually death, if left untreated [1]. Contrast-enhanced CT scan is an essential diagnostic tool, since it points out retroperitoneal hematoma (high-density homogenous mass) and the presence of active bleeding (contrast leakage). Whenever active bleeding is put in evidence, urgent angiography is essential to identify the exact source, and to perform transcatheter arterial embolization. Since these patients often suffer renal insufficiency, a particular thought must be turned to the need of dialysis for contrast washout. Direct surgical management is difficult for both identification and control of the bleeding source, and it is thus not recommended in first place [1-7]. Nevertheless, surgery can be useful in a second time, for abdominal decompression and hematoma evacuation, as in our case. Conservative treatment can be attempted in stable patients with no signs of compartment syndrome.

Spontaneous LAR is an extremely rare entity in the adult population which exact incidence and underlying mechanisms are still unclear. Old age, diabetes, retroperitoneal neoplasm, iatrogenic or accidental trauma, coagulopathy, antiplatelet or anticoagulation therapy, and hemodialysis are regarded as risk factors [2-4]. Muscle strain has also been advocated as a possible contributor to LAR [6]. Whenever LAR occurs in the absence of an underlying cause as trauma or malignancy, it seems to be associated with old age, ESDR requiring hemodialysis, and anticoagulation [5]. Regardless the cause, mortality is about 50% and seems more frequent in the case of antiplatelet or anticoagulation therapy [1]. Only one case of LAR in a post-transplant patient has been reported to date [8]. It was the

case of a 48-years old woman that underwent acute rejection of the grafted kidney, requiring hemodialysis using heparin, steroid pulses, and plasmapheresis. Our patient is the first reported case of LAR in children. Major risk factors were anticoagulation with LWMH and baseline coagulopathy, ESRD without dialysis, and recent history of surgery. Nevertheless, LAR occurred at 13th POD after graft ablation. This might suggest that coagulation disorders, spontaneous and/or drug-induced, in association with ESDR and recent surgery, enhance the risk of LAR, even in younger patients.

Conclusion

Spontaneous LAR is a rare event, even in adult population. Impaired renal function and anticoagulation therapy in association with a recent story of renal transplantation might represent important risk factor, especially for younger patients. Immediate identification and appropriate intervention are mandatory to reduce morbidity and mortality.

References

1. Kim JY, Lee SA, Hwang JJ, Park JB, Park SW, Kim YH, et al. Spontaneous lumbar artery rupture and massive retroperitoneal hematoma, successfully treated with arteriographic embolization. *Pak J Med Sci.* 2019;35(2):569-74.
2. Hwang NK, Rhee H, Kim IY, Seong EY, Lee DW, Lee SB, et al. Three cases of spontaneous lumbar artery rupture in hemodialysis patients. *Hemodial Int.* 2017;21(1):E18-E21.
3. Surani S, Estement B, Manchandan S, Sudhakaran S, Varon J. Spontaneous extraperitoneal lumbar artery hemorrhage. *J Emerg Med.* 2011;40(6):e111-4.
4. Fan WX, Deng ZX, Liu F, Liu RB, He L, Amrit B, et al. Spontaneous retroperitoneal hemorrhage after hemodialysis involving anticoagulant agents. *J Zhejiang Univ Sci B.* 2012;13(5):408-12.
5. Fortina M, Carta S, Del Vecchio EO, Crainz E, Urgelli S, Ferrata P. Retroperitoneal hematoma due to spontaneous lumbar artery rupture during fondaparinux treatment. Case report and review of the literature. *Acta Biomed.* 2007;78(1):46-50.
6. Yamamura H, Morioka T, Yamamoto T, Kaneda K, Mizobata Y. Spontaneous retroperitoneal bleeding: a case series. *BMC Res Notes.* 2014;7:659.
7. Isokangas JM, Perälä JM. Endovascular embolization of spontaneous retroperitoneal hemorrhage secondary to anticoagulant treatment. *Cardiovasc Intervent Radiol.* 2004;27(6):607-11.
8. Ueda N, Naito H, Sugimoto M. Spontaneous lumbar artery rupture in a kidney transplant patient: A case report. *Urol Case Rep.* 2019;29:101092.