

Case Report

Surgical Management of Blunt Duodenal Injuries in Children

Jonas Povilavičius*

Department of Pediatric Surgery, Children's Hospital, Affiliate of Vilnius University Hospital Santaros Klinikos, Vilnius, Lithuania

Abstract

Background/purpose: Duodenal injury occurring secondary to blunt abdominal trauma continues to pose a diagnostic challenge. The purpose of this study is to evaluate the cause, radiologic findings, and management of duodenal injuries in our hospital. We report five cases.

Methods: A retrospective review was performed of perforated duodenal injuries in children less than 18 years of age from 1983 to 2020.

Results: We treated five children for duodenal injuries. There were four penetrating injuries. One child had duodenum obstruction symptoms secondary to retroperitoneal hematoma. Three patients underwent operative management by primary repair; one patient required duodenojejunostomy with Braun's anastomosis, and one child underwent evacuation of the retroperitoneal hematoma. We recorded no deaths.

Conclusion: Duodenal injuries were predominantly blunt in children. There were no deaths. When surgery was required, primary repair was usually feasible.

Keywords: Blunt abdominal trauma; Duodenal injury; Children trauma; Ultrasonography

Introduction

The most common mechanism of injury during childhood is a blunt abdominal trauma, which is a leading cause of death and may cause injury to duodenum [1]. Which pose a diagnostic and therapeutic challenge. Injury to the gastrointestinal tract occurs in less than 1% of injured children, with duodenum being the fourth most commonly injured intra-abdominal organ, overall presenting from 2% to 10% of trauma cases. Canty et al. [2] reported an incidence of duodenal trauma as 0.16% of all patients with trauma per year.

Case Presentation

Case 1

Ambulance admitted a ten-year-old girl to the emergency department, with a four-hour history of nausea and upper abdominal pain. The mechanism of injury was a handlebar impact. We observed paleness of the skin and bruising in the epigastric area. After an hour, she developed abdominal distension and signs of peritonitis. We performed an emergency laparotomy and found a four cm rupture of the second part of duodenum, which we repaired by primary closure in two layers and drainage of the retroperitoneal space. On the sixth postoperative day, duodenal fistula developed, which we treated conservatively. The patient was discharged home after 31 days of hospitalization.

Citation: Povilavičius J. Surgical Management of Blunt Duodenal Injuries in Children. *Int J Pediatr Surg.* 2020;1(2):1007.

Copyright: © 2020 Jonas Povilavičius

Publisher Name: Medtext Publications LLC

Manuscript compiled: Sep 04th, 2020

***Corresponding author:** Jonas Povilavičius, Department of Pediatric Surgery, Children's Hospital, Affiliate of Vilnius University Hospital Santaros Klinikos, Vilnius, Lithuania, Tel: +37 061559844; E-mail: jonas.povilavicius@gmail.com

Case 2

Ambulance transported an eight-year-old boy to an emergency department after a car accident, which occurred 1.5 hours ago. The child was conscious, moaning, although lethargic. An abdominal radiography showed free-air intraperitoneally and recent fractures of hip and forearm. Ultrasound of the abdominal cavity showed the rupture of the spleen, peritoneal fluid in right lateral space, and a sizeable retroperitoneal phlegmon. We performed emergency laparotomy and found a three cm rupture of the retroperitoneal part of duodenum, which we repaired by jejunoduodenostomy with Braun's anastomosis. We also performed gastrostomy with retroperitoneal space drainage (Figure 1). We treated the patient for nine days in the intensive care unit. During the first three days, we administered nutrition parenterally; afterward, we fed him through a jejunal tube and removed it after eight days. We removed drains from retroperitoneal space on the fifth postoperative day and closed gastrostomy on the tenth, respectively. The patient went home after 35 days of treatment in good condition.

Case 3

Ambulance admitted a 12-year-old boy to the emergency department because of abdomen pain. A basketball hoop fell on the child's stomach four hours ago. Plain abdominal radiography and ultrasonography did not reveal any severe intra abdominal injury. After three hours of observation, he developed abdominal distension and signs of peritonitis. We performed an emergency laparotomy because we suspected a duodenal injury and found retroperitoneal hematoma and two cm rupture of the second part of the duodenum, which we repaired by primary closure and drainage. The postoperative period was without any complications. The patient went home after 12 days in good condition.

Case 4

Ambulance admitted a 12-year-old unconscious boy to the emergency room. The ambulance found him lying in the street, while the circumstances of the incident were unclear. Radiography showed

bilateral pneumothorax, L5 fracture, left and right tibial fractures, left humerus fracture, and forearm fractures. We performed an emergency laparotomy and a splenectomy because of hemodynamical instability. Symptoms of intestinal obstruction appeared on the first postoperative day. Ultrasonography showed retroperitoneal hematoma compressing duodenum. We did relaparotomy with drainage of hematoma. However, symptoms of intestinal obstruction reappeared after five days, resulting in second relaparotomy. We performed division of adhesions, elimination of abscess, and drainage of the pancreas. The patient spent 28 days in the intensive care unit and was discharged home on the 57 postoperative days.

Case 5

Ambulance admitted an 11-year-old boy to the emergency department of a district's hospital, with a four-hour history of nausea and upper abdominal pain. The mechanism of injury was a handlebar impact. The boy had nausea and bruising in the epigastric area. After 17 hours of conservative treatment, the ambulance transferred him to the republic hospital. The boy complained of abdominal pain; physical examination revealed abdominal distension and gross signs of peritonitis. CT showed free air in the retroperitoneal space. We performed an emergency laparotomy and found a 1.2 cm rupture of the fourth part of the duodenum, which was repaired by primary closure in two layers and drainage of retroperitoneal space. There were no complications in the postoperative period. The boy was discharged home after ten days in good condition.

Discussion

The most common mechanism of injury during childhood is a blunt abdominal trauma, which is a leading cause of death and may cause injury to duodenum [1]. In 80% of cases, an injury to a solid organ is observed [2]. In this report, we presented three cases involving an injury to the other solid organs (60%). Injury to the gastrointestinal tract occurs in less than 1% of injured children [1-3], with duodenum being the fourth most commonly injured intra-abdominal organ, overall presenting from 2% to 10% of trauma cases. Canty et al. [2] reported an incidence of duodenal trauma as 0.16% of all patients with trauma per year.

The majority of BDIs in children result from motor vehicle collisions, during which a child experiences compressing forces or negative acceleration, another part consists of direct blows [2]. More precisely, hematoma results from compression of the duodenum against the vertebral column, whereas perforations potentially develop from shearing forces or because of simultaneous closure of the pylorus and the fourth portion of the duodenum which contributes to increased intraluminal pressure and a "blowout". During direct blow or by abdominal wall compression, kinetic forces push duodenum against the spine producing injury to the second or the third parts of the duodenum, meanwhile, when a negative acceleration effects duodenum, it moves anteriorly away from the retroperitoneal holding structures, and this causes a rupture of the third and fourth parts, respectively. We reported two patients (40%) who were involved in a car accident. One of them presented with an indeterminate circumstance of injury, so we assumed that a vehicle struck him. We reported three patients (60%) who experienced direct blow: two fell off the bike and struck the steering wheel, and a basketball hoop fell on the other, injuring the second part of duodenum. We classified injuries by using the Organ Injury Scale for the Duodenum established in 1990 by the Organ Injury Scaling Committee of the American Association for the Surgery of Trauma (Table 1). According to Ivatury, complicated are

all of III-IV grade injuries, duodenal injuries involving the pancreas, injuries with damage of the common bile duct, and the periampullary area, and finally, small, early undiagnosed lacerations with late excessive inflammation and edema [4,5]. There were two (40%) such cases, while we graded remaining injuries as a grade I-II. Blunt duodenal injuries pose a diagnostic and therapeutic challenge, partly due to nonspecific, subtle clinical and radiographic findings, associated injuries, unreliable history, and retroperitoneal location, which may lead to delay in diagnosis and treatment [6]. In three patients (60%), we diagnosed duodenal injury in the time frame of three hours upon arrival. We operated one patient after an hour of arrival because he had signs of peritonitis. Another patient had hemodynamic instability, so he underwent laparotomy and splenectomy; nevertheless, after three days, we observed signs of bowel obstruction, which resulted in relaparotomy, during which we found retroperitoneal hematoma that was compressing duodenum (Table 2). As mentioned before, associated injuries are frequent and influence overall morbidity and mortality [6]. We diagnosed three children with an additional injury of a solid organ; one patient had multiple fractures of bones; despite that, there were no deaths. Literature indicates that early symptoms and physical findings that include nausea, vomiting, abdominal pain, and tenderness are common, although not specific to any grade of duodenal injury [7]. In our report, all conscious children complained of abdominal pain, while only three had abdominal tenderness. Studies suggest that elevated levels of serum amylase might provide additional information on duodenal injury; however, serum amylase generally might be elevated due to associated abdominal injuries [8]. In our cases, blood tests revealed elevated blood amylase only in one patient (20%). The main suggestive findings of intestinal injury on CT, excluding patients with an injury to a solid organ, are the presence of mural thickening, retroperitoneal air, intraperitoneal air, and free intraperitoneal fluid. In the absence of peritonitis and hemodynamic instability, a CT scan with intravenous and oral contrast is the most sensitive diagnostic modality in a suspected traumatic retroperitoneal pathology [9]. In our report, we diagnosed only single duodenal injury with a CT scan; meanwhile, other patients underwent laparotomy due to signs of peritonitis; besides, we found an echoscopy of the abdomen to be the most useful diagnostic tool in abdominal injuries duodenum. Coggill et al. [6] have advocated conservative management of duodenal injuries, concluding that the vast majority of uncomplicated cases can be managed by primary repair (duodenorrhaphy) with or without pyloric exclusion. He also suggested treating complicated and combined duodenum injuries with pyloric exclusion and the formation of gastrojejunostomy or pancreaticoduodenectomy [5,6,10]. Specific indications regarding pyloric exclusion are the combined duodenal and pancreatic injuries, operational delay of more than 24 hours, compromised blood supply, and a high-energy trauma, moreover, in order to decompress the stomach, the surgeon must perform gastrostomy and feeding jejunostomy. We managed three children (60%) by the primary repair of the duodenum without pyloric exclusion. Frequent postoperative complications include formation of fistula in 6% to 10% of patients, abscess, dehiscence of the duodenum, development of peritonitis, and sepsis [3,6], however, pyloric exclusion with gastrojejunostomy reduces fistula rates to less than 5% and overall mortality to 19%. A significant complication occurring after pyloric exclusion is the marginal ulceration at the anastomotic site of gastrojejunostomy, which Martin et al. [10] reported in up to 10% of patients. Other less common complications encompass pancreatitis, bleeding, insufficiency of anastomosis, and obstruction of the stomach. In

our case, no postoperative complications occurred in two children (40%). Postoperative complications occurred in three patients; the first child developed fistula of the duodenum, which we managed conservatively, the second patient developed bowel obstruction due to retroperitoneal hematoma, and an abscess of the pancreas formed in the third patient. Ultimately, all children recovered and discharged home in good condition.

Table 1: Duodenal Organ Injury Scale: American Association for the Surgery of Trauma.

Injury grade	Injury difficulty	Injury description
I	Hematoma	Involving single portion of duodenum
	Laceration	Partial thickness, no perforation
II	Hematoma	Involving more than one portion
	Laceration	Disruption <50% of circumference
III	Laceration	Disruption 50% to 75% circumference of D2
		Disruption 50% to 100% circumference of D1, D3, D4
IV	Laceration	Disruption >75% circumference of D2
		Involving ampulla or distal common bile duct
V	Laceration	Massive disruption of duodenopancreatic complex
	Vascular	Devascularization of duodenum

Table 2: Duodenal organ injury scale and choice of primary operative procedure (among patients who lived to repair).

Class	Injury	Technique
I	Small hematoma (single segment), serosal injury	No procedure (67%)
		Duodenorrhaphy (28%) Drain hematoma (5%)
II	Large hematoma (>1 segment), <25% disruption of the duodenal wall	No procedure (1%)
		Duodenorrhaphy (81%)
		Pyloric exclusion (17%) Drain hematoma (1%)
III	25% to 75% disruption D2 duodenal wall, 25% to 100% disruption D1, D3, D4 duodenal wall	Duodenorrhaphy (55%)
		Pyloric exclusion (34%)
		Duodenojejunostomy (9%)
		Pancreatoduodenectomy (2%)
IV	>75% disruption D2 duodenal wall, involvement of the ampulla or distal common bile duct	Duodenorrhaphy (50%)
		Pyloric exclusion (50%)
V	Devascularization of duodenum, massive disruption of pancreaticoduodenal complex	Pancreatoduodenectomy (100%)

References

- Grosfeld JL, Rescorla FJ, Karen KW, Vane DW. Gastrointestinal injuries in childhood: Analysis of 53 patients. *J Pediatr Surg.* 1989;24(6):580-3.
- Canty TG Sr, Canty TG Jr, Brown C. Injuries of the gastrointestinal tract from blunt trauma in children: a 12-year experience at a designated pediatric trauma center. *J Trauma.* 1999;46(2):234-40.
- Vaughan GD, Frazier OH, Graham DY, Mattox KL, Petmecky FF, Jordan GL. The use of pyloric exclusion in the management of severe duodenal injuries. *Am J Surg.* 1977;134(6):785-90.
- Ivatury RR. Duodenal injuries: Small but lethal lesions. *Cir Gen.* 2003;25(1):59-65.
- Moore EE, Cogbill TH, Malangoni MA, Jurkovich GJ, Champion HR, Gennarelli TA, et al. Organ injury scaling, II: Pancreas, duodenum, small bowel, colon, and rectum. *J Trauma.* 1990;30(11):1427-9.
- Cogbill TH, Moore EE, Feliciano DV, Hoyt DB, Jurkovich GJ, Morris JA, et al. Conservative Management of Duodenal Trauma: a Multicenter perspective. *J Trauma.* 1990;30(12):1469-75.
- Shilyansky J, Pearl RH, Kreller M, Sena LM, Babyn PS. Diagnosis and management of duodenal injuries in children. *J Pediatr Surg.* 1997;32(6):880-6.
- Snyder WH, Weigelt JA, Watkins WL, Bietz DS. The surgical management of duodenal trauma: precepts based on a review of 247 cases. *Arch Surg.* 1980;115(4):422-9.
- Mirvis SE, Gens DR, Shanmuganathan K. Rupture of the bowel after blunt abdominal trauma: diagnosis with CT. *AJR Am J Roentgenol.* 1992;159(6):1217-21.
- Martin TD, Feliciano DV, Mattox KL, Jordan GL. Severe duodenal injuries. Treatment with pyloric exclusion and gastrojejunostomy. *Arch Surg.* 1983;118(5):631-5.

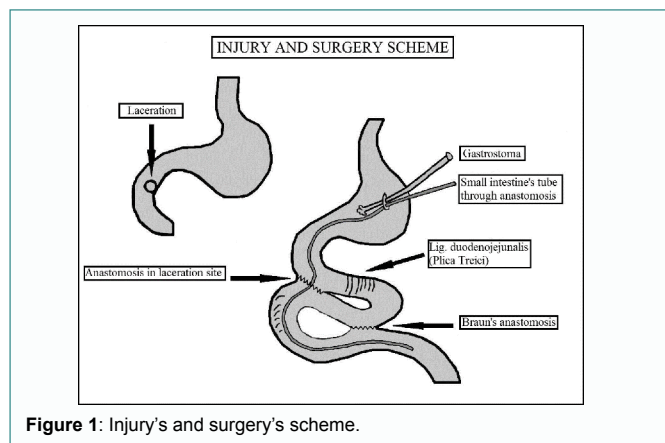


Figure 1: Injury's and surgery's scheme.