

## Research Article

# Temporary Overlay Lyophilized Human Amniotic Membrane Technique for Macular Hole: A Preliminary Study

Sarah Ayello-Scheer<sup>1\*</sup>, Sami Saad<sup>1</sup>, Francois Boussion<sup>1</sup>, Rana Saad<sup>1</sup>, Michel Paques<sup>1,2</sup> and Stephane Bertin<sup>1</sup>

<sup>1</sup>Centre National d'Ophthalmologie des Quinze-Vingts, France

<sup>2</sup>Institut de la Vision, France

## Abstract

**Purpose:** To assess the efficacy and safety of the overlay epimacular human Amniotic Membrane (hAM) technique for Persistent Macular Hole (PMH) that already underwent pars plana vitrectomy with internal limiting membrane peeling and gas endotamponade.

**Methods:** A 23-gauge pars plana vitrectomy was performed with implantation of a lyophilized hAM patch (Visio-Amtrix, TBF and France) over the PMH into the epimacular space. C2F6 was used as endotamponade. Best-Corrected Visual Acuity (BCVA) and OCT were assessed preoperatively.

**Results:** Four eyes of 4 patients with PMH were enrolled from June 2019 to December 2019 with one year follow-up. Optical coherence tomography examinations showed that the PMHs closed in 3 of the 4 patients (75%). BCVA improved in 3 cases at 12 months and 3 patients reported improvement of the central scotoma and metamorphopsia. Mean BCVA improved from  $1.67 \pm 0.44$  logarithm of the Minimum Angle of Resolution (logMAR) (20/800 Snellen equivalent) to  $0.85 \pm 0.45$  logMAR (20/125 Snellen equivalent) 1 months after surgery. The sole patient that had persistence of the PMH had hAM migration inferiorly at M1 postoperatively. Due to a decrease in BCVA during the follow-up, the hAM patch was easily removed in 2 cases with recovery of the best visual acuity found during follow-up.

**Conclusion:** We report promising preliminary results following overlay epimacular lyophilized hAM plug technique to close PMH with poor surgical prognosis. The good anatomical and functional improvement and high safety of the technique highlight the need to develop and evaluate the technique further, and to determine when to remove the hAM.

**Brief summary statement:** Management of persistent macular holes is a real challenge. We report promising preliminary results using a temporary epimacular lyophilized human amniotic patch in 4 patients over 12 months of follow-up. Further developments are needed to improve this technique and to determine the best timing for the patch removal when needed.

**Keywords:** Persistent macular hole; Refractory macular hole; Lyophilized human amniotic membrane; hAM patch; hAM plug

## Introduction

If the failure rate of primary surgery in idiopathic macular hole is less than 10%, the treatment of Persistent Macular Holes (PMH) remains a tremendous challenge for vitreoretinal surgeons. The use of various adjuvant or biological tissue to improved hole closure rates has been reported by various authors in PMH that have already failed standard macular hole surgery with Internal Limiting Membrane (ILM) peeling and gas tamponade, including the insertion of a free ILM patch [1] an autologous neurosensory retinal free flap [2] or autologous capsular lens fragments [3] into the PMH. These modern approaches for PMH yielded interesting outcomes with a reported anatomical and functional success rate of 60% to 90%. In addition, autologous serum has been proposed in various vitreoretinal surgeries

including macular hole surgery as an additive agent that exerts trophic support for retinal and Retinal Pigment Epithelial (RPE) cells to improve the hole closure rate [4].

Fresh or lyophilized Human Amniotic Membranes (hAM) are widely used in the anterior segment field as an anti-inflammatory agent, healing promoter and mechanical scaffold for cell proliferation in persistent corneal epithelial defects. hAM can be used as an inlay corneal graft or an overlay corneal patch [5]. In the inlay grafting technique, the basement membrane of the hAM is intended to act as a substrate or scaffold in order to facilitate migration of epithelial cells. The inlay hAM graft is ultimately incorporated into the host tissue, leading to corneal fibrosis and limiting the visual recovery. In the overlay patching technique, the hAM acts as a temporary biological healing and anti-inflammatory promoter for epithelial cells that falls off over a period of time and is not definitely integrated to the host. Some studies have demonstrated that hAM is also an adequate support to RPE growth and differentiation [6].

Very recently, in vivo hAM plug transplantation was described as a novel technique for PMH repair. Rizzo and colleagues [7] were the first to describe this technique in October 2019, where they inserted the hAM plug under the subretinal space ("inlay" hAM technique). The hAM plug seems to act as a mechanical and biological support for the neuroretina. This technique yielded promising anatomical results with the PMH closure in almost 90% of cases. In February 2020, Moharram and colleagues [8] described another technique

**Citation:** Ayello-Scheer S, Saad S, Boussion F, Saad R, Paques M, Bertin S. Temporary Overlay Lyophilized Human Amniotic Membrane Technique for Macular Hole: A Preliminary Study. Clin Ophthalmol J. 2023;3(1):1023.

**Copyright:** © 2023 Sarah Ayello-Scheer

**Publisher Name:** Medtext Publications LLC

**Manuscript compiled:** Feb 23<sup>rd</sup>, 2023

**\*Corresponding author:** Sarah Ayello-Scheer, Centre National d'Ophthalmologie des Quinze-Vingts, Institut de la Vision, Paris, France, E-mail: sscheer@15-20.fr

where they preferred to place the hAM over the retinal posterior pole ("overlay" hAM technique), yielding to a success rate of 93% in 14 eyes with myopic macular holes with recurrent retinal detachment. This overlay approach seems more attractive than the first one as the inlay technique suffers from three major pitfalls. First, the hAM insertion under the retina is technically challenging, even for experimented vitreoretinal surgeons. Second, the inlay technique seems to stimulate the PMH closure *via* the induction of a retinal fibrosis, which could limit the postoperative visual recovery [9]. Third, the hAM plug cannot be retracted easily once placed into the subretinal space, raising concerns towards the long-term tolerance of the plug in this very recent technique.

We hypothesized that a hAM patch placed over the retina in the epimacular space may improve anatomical and functional outcomes in advanced PMH surgical cases. We report the clinical and anatomical preliminary data of 4 patients with PMH who underwent overlay lyophilized hAM transplantation.

## Materials and Methods

This is a prospective, interventional, consecutive case series conducted at the Quinze-Vingts National Hospital of Ophthalmology, Paris, France. All the patients signed an informed consent. The study been approved by the Ethics Committee of the French Society of Ophthalmology (IRB 00008855), in accordance with the tenets of the Declaration of Helsinki.

The patients underwent a standard 3-ports, 23-gauge transconjunctival pars plana vitrectomy (Eva<sup>®</sup>, DORC International B.V., Zuidland, The Netherlands) under peribulbar anesthesia and hAM plug transplantation in the epimacular space on the persistent macular hole. All the surgical procedures were performed by the same experienced vitreoretinal surgeon (S. A-S.).

Preoperatively, an ophthalmic history and a complete ophthalmic examination including refraction with assessment of best-corrected visual acuity (BCVA, Snellen converted in logarithm of the Minimal Angle of Resolution [logMAR] for analysis), Goldmann applanation tonometry, standard fundus dilated ophthalmic examination, spectral domain OCT (AngioVue Optovue<sup>®</sup>, Fremont, CA or Spectralis, Carl Zeiss Meditec Inc., California, USA) analysis of the macular hole with an accurate measurement of the internal and external diameter according to the IVTS Group and an ultrawide retinography (CLARUS 500<sup>®</sup>, Carl Zeiss Meditec Inc., California, USA). All patients were examined preoperatively and at 1 week, 1, 3 months, 6 months, 9 months, 12 months postoperatively.

All patients underwent a prior first surgery with a complete vitrectomy with extensive vitreous base shaving and ILM peeling after staining with vital dyes (Membrane Blue Dual<sup>®</sup>, Horus Pharma, Saint-Laurent du Var, France). A patch of lyophilized amniotic membrane (Visio-AMTRIX<sup>®</sup>, TBF, Mions, France) was cut with simple surgical scissors, about 2 mm in size. After removing the valve, the hAM patch was inserted with a vitreoretinal forceps through the trocar into the vitreous chamber. When the hAM is in vitreous cavity, it rolls immediately and had to be manipulated under perfluorocarbon (PFCL) (EFTIAR Dk-line<sup>®</sup>, DORC, Issy-les-Moulineaux, France), inside the vitreous cavity. The hAM was placed basement membrane side up over the macular hole. Fluid-gas exchange with 16% perfluoroethane gas (C2F6, Arceole<sup>®</sup>, ARCADOPHTA and Toulouse, France) was performed at the end of the procedure. The patient was asked to maintain face-down positioning for the first 7 days after

surgery. An intraoperative retinal OCT scan was performed to check the correct position of the amniotic membrane plug over the PMH.

In 2 cases, the hAM removal was performed due to a decrease in BCVA during the follow-up. The removal surgery was performed easily *via* a transconjunctival 25-gauge sutureless vitrectomy with Grieshaber microsurgical forceps at 9 months (case 1) and 6 months (case 4) postoperatively.

## Results

Four consecutive female patients were included in the study from June 2019 to December 2019 (Table 1). The mean age was  $62.4 \pm 3.7$  years (range 62 to 71 years). Mean preoperative macular hole OCT size was of  $853.8 \mu\text{m} \pm 179.8 \mu\text{m}$  (range 559  $\mu\text{m}$ -1079  $\mu\text{m}$ ). Three patients had already undergone PPV with ILM peeling and C2F6 gas tamponade prior to the overlay hAM implantation surgery, and were pseudophakic with capsulotomy. One had a macular hole with a poor prognosis with a size of 1079  $\mu\text{m}$  according to the IVTS Group and evolution for more than one year (case 4).

### BCVA outcomes

The mean preoperative BCVA was  $1.67 \text{ logMAR} \pm 0.44 \text{ logMAR}$  (20/800 Snellen equivalent) ranging from 1.00 logMAR to 2.00 logMAR (20/200 to 20/2000 Snellen equivalent) and improved to  $0.85 \text{ logMAR} \pm 0.45 \text{ logMAR}$  (20/125 Snellen equivalent) 1 months after surgery. One patient had a migration of the hAM at 1 month with an improvement at 1 month followed by a decrease of the BCVA to the preoperative level. None of the patients who had a complete closure of the PMH complained about metamorphopsia post operatively.

### Anatomical outcomes

During the first 1 to 3 months, a retinal ingrowth on the macular hole margin under the hAM patch was reported. The PMH closure was reported in 3 cases over 4 (Figure 1). An inferior migration of the hAM patch was observed in two patients (cases #2 and #4, Figure 2) at 7 days and 1 month postoperatively respectively. However, we reported in these 2 cases an improvement of the anatomical aspect of the PMH with improvement of the PMH borders in the first case and the closure of the PMH in the second case as well as an improvement of the visual acuity in both cases, from 20/2000 preoperatively to 20/400 and from 20/400 to 20/40 postoperatively at 1 month respectively.

### Safety and adverse events

The removal of the hAM patch was performed in two cases for a decrease in BCVA at 9 months (case 1) and 6 months (case 4) postoperatively with a total recovery of the postoperative BCVA after the surgical removal in these cases (Table 1). Figure 3 reports the macular OCT modifications before and after the hAM patch removal. No eyes had intraoperative or postoperative adverse events such as endophthalmitis, hypotony, intraocular pressure elevation, or other serious events during the follow-up period.

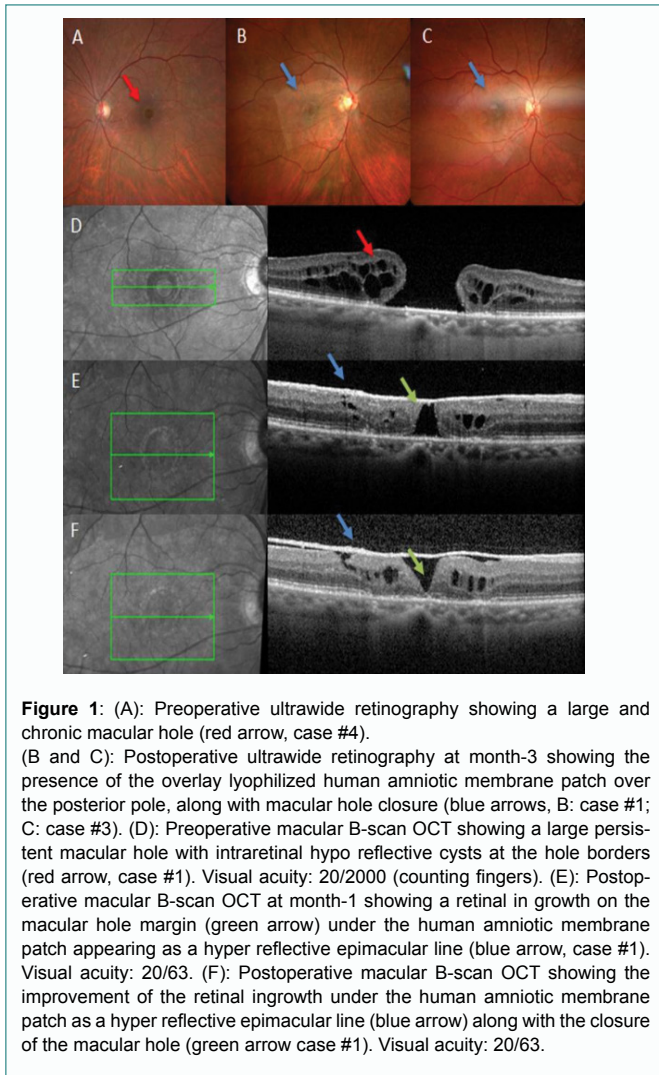
## Discussion

Human amniotic membrane has been used in corneal pathologies since almost eight decades. Very recently, the use of hAM in retinal pathologies as a promoter of retinal and RPE cell proliferation and differentiation has been proposed by authors. In particular, the use of hAM transplantation techniques have been described in 2019 (inlay hAM plug technique) [7] and 2020 (overlay hAM patch technique) [8]. Lyophilized hAM are readily available worldwide and are easier to manipulate inside the eye than other substrates used to close PMH, such as fresh hAM, ILM plugs, autologous retinal plugs, or capsular

**Table 1:** Preoperative Demographic Data and Findings, and Results.

Case	Preoperative data		BCVA	Postoperative data					Anatomical closure
	Age (years)	Macular hole size (µm)		M1 BCVA	M3 BCVA	M6 BCVA	M9 BCVA	M12 BCVA	
1	71	559	20/2000 (CF)	20/63	20/63	20/80	20/100*	20/63	Yes
2 †	64	988	20/2000 (CF)	20/400	20/400	20/2000 (CF)	20/2000 (CF)	20/2000 (CF)	No
3 ‡	63	789	20/400	20/40	20/40	20/40	20/40	20/40	Yes
4	62	1338	20/200	20/400	20/400	20/500*	20/100	20/100	Yes

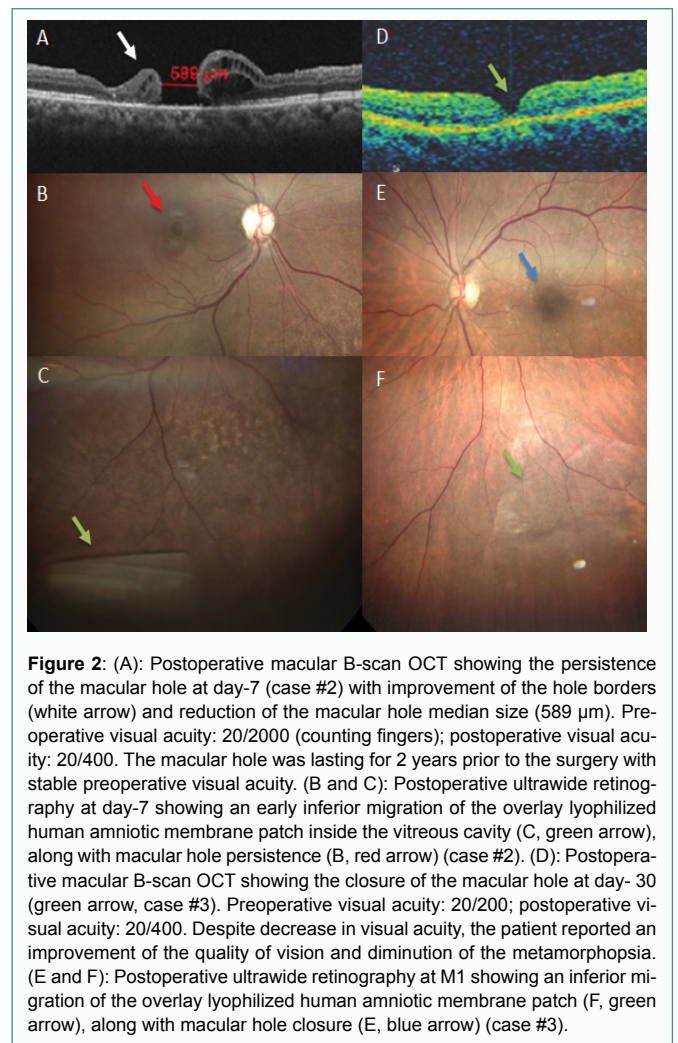
BCVA: Best-Corrected Visual Acuity (Snellen equivalent); CF: Counting Fingers; †: Inferior migration of the human amniotic membrane patch at day-7; ‡: Inferior migration of the human amniotic membrane patch at day-30; \*: Surgical removal of the human amniotic membrane patch



**Figure 1:** (A): Preoperative ultrawide retinography showing a large and chronic macular hole (red arrow, case #4). (B and C): Postoperative ultrawide retinography at month-3 showing the presence of the overlay lyophilized human amniotic membrane patch over the posterior pole, along with macular hole closure (blue arrows, B: case #1; C: case #3). (D): Preoperative macular B-scan OCT showing a large persistent macular hole with intraretinal hypo reflective cysts at the hole borders (red arrow, case #1). Visual acuity: 20/2000 (counting fingers). (E): Postoperative macular B-scan OCT at month-1 showing a retinal in growth on the macular hole margin (green arrow) under the human amniotic membrane patch appearing as a hyper reflective epimacular line (blue arrow, case #1). Visual acuity: 20/63. (F): Postoperative macular B-scan OCT showing the improvement of the retinal ingrowth under the human amniotic membrane patch as a hyper reflective epimacular line (blue arrow) along with the closure of the macular hole (green arrow case #1). Visual acuity: 20/63.

lens fragments.

In our cohort of 4 patients treated with overlay hAM patch technique, the persistent macular hole or macular hole with poor prognosis was resolved in 75% of cases. An early migration of the hAM patch inferiorly in the vitreous cavity was reported at day-7 in the only case of closure failure of the PMH. The case of inferior migration was reported at 1 month, in the patient who had a poor prognosis for the closure, and the macular hole was closed even if the hAM migrated. We reported an improvement of the anatomical aspect of the PMH as well as the visual acuity after the surgery in these two cases of hAM migration. No glial or fibrosis process were reported in our cohort. During the follow-up period, the neuroretina over the hAM plug differentiated to form retinal layers, in particular in the outer layer such as the external limiting membrane and ellipsoid

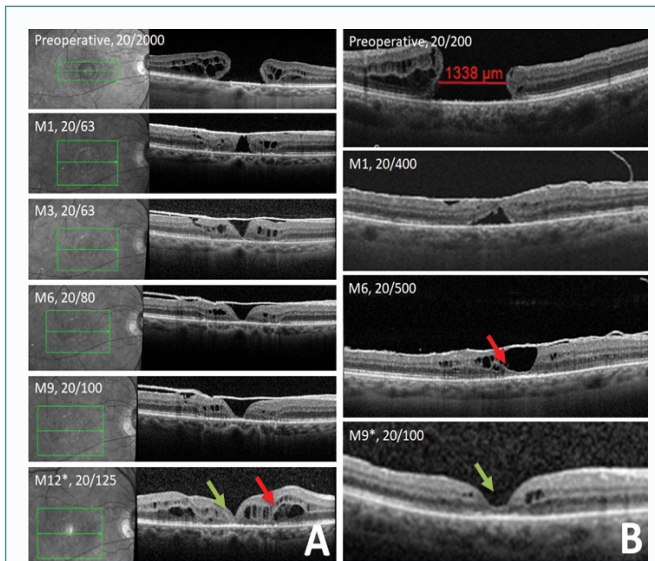


**Figure 2:** (A): Postoperative macular B-scan OCT showing the persistence of the macular hole at day-7 (case #2) with improvement of the hole borders (white arrow) and reduction of the macular hole median size (589 µm). Pre-operative visual acuity: 20/2000 (counting fingers); postoperative visual acuity: 20/400. The macular hole was lasting for 2 years prior to the surgery with stable preoperative visual acuity. (B and C): Postoperative ultrawide retinography at day-7 showing an early inferior migration of the overlay lyophilized human amniotic membrane patch inside the vitreous cavity (C, green arrow), along with macular hole persistence (B, red arrow) (case #2). (D): Postoperative macular B-scan OCT showing the closure of the macular hole at day-30 (green arrow, case #3). Preoperative visual acuity: 20/200; postoperative visual acuity: 20/400. Despite decrease in visual acuity, the patient reported an improvement of the quality of vision and diminution of the metamorphopsia. (E and F): Postoperative ultrawide retinography at M1 showing an inferior migration of the overlay lyophilized human amniotic membrane patch (F, green arrow), along with macular hole closure (E, blue arrow) (case #3).

zone. This process can probably be associated with the visual acuity improvement found during the follow-up. All patients were satisfied with their postoperative visual acuity and reported a subjective improvement of metamorphopsia and quality of vision, although we reported stability in the objective visual acuity the only case of early patch migration.

Several previous studies have demonstrated that hAM secretes growth factors or express adhesion molecules than promote corneal epithelial differentiation, proliferation and healing [5]. Similarly, recent studies reported that hAM could play a similar role toward retinal and RPE cells [6]. Some authors have described retinal fibrosis and pigment epithelium dystrophy in the macular area, after internal limiting membrane autologous transplantation for persistent macular hole, which can affect final visual recovery [9,10]. Similarly, fibrosis and glial process can be observed in the inlay hAM plug technique





**Figure 3:** (A): Preoperative and postoperative macular B-scan OCT (case #1) showing closing of the persistent macular hole with improvement of the visual acuity with a maximum at M3 postoperatively. Removal of the overlay lyophilized human amniotic membrane patch at M9 after the decrease of the visual acuity. After removal (\*), the hole remained closed and the visual acuity improved to the M3 postoperative level. (B): Preoperative and postoperative macular B-scan OCT (case #4) showing a large macular hole (size 1338  $\mu\text{m}$ ) with closing of the hole and improvement of the visual acuity after surgery. At M6, we report atrophy of the retinal layers (red arrow) with a decrease in visual acuity. After removal of the overlay lyophilized human amniotic membrane patch (\*), we report an improvement of the atrophy and the visual acuity along with the closure of the hole (green arrow).

[9]. On the contrary, we do not report any of these pathological findings following overlay hAM patching technique. We do not report any complications such as intraoperative complications, retinal detachment or endocular inflammation of the hAM patch in this preliminary study. However, we report a decrease in BCVA after month-3 in two patients (50%), and our results are suggestive to remove the hAM patch at M3 in order to avoid a potential iatrogenic retinal toxicity of the hAM.

To the best of our knowledge, only 12 studies have been reported concerning hAM plug in PMH surgery to date. Only one [8] described the outcomes of overlay hAM patching technique for high myopic PMH with recurrent retinal detachment, with a functional success of 86% (12/14 eyes) and an anatomical success of 93% (13/14 eyes) over a follow-up period of 6 months but the evolution of the BCVA throughout the follow-up is not reported in this study. We reported the second case series using overlay hAM patch technique for treatment of non-complicated idiopathic PMH with a functional success and an anatomical success of 75% (3/4 eyes). To our knowledge, our cohort is the first to suggest the removal of the hAM, with a maximum of efficacy of the hAM overlay patch around month-3 postoperatively. This study is also the first to report the use of lyophilized hAM for PMH to date. Limitations for this study include small sample size, short follow-up period and lack of a control group. However, our preliminary results are encouraging and this technique seems to be more adequate than the inlay hAM plug technique because it is a reversible and less aggressive approach than the inlay amniotic membrane plug transplantation initially described by Rizzo et al. [7]. Furthermore, our preliminary results suggest that the hAM overlay patch may lead to late atrophy and should be removed after the third month postoperatively.

## Conclusion

We believe that the mechanical scaffold role as well as the growth factors secreted by the hAM can induce retinal healing, increase the retinal activity and ultimately the closure rate of advanced cases of macular hole. Overlay hAM transplantation seems to be a valid option in persistent macular hole surgery. Further studies are mandatory to understand the interaction between the amniotic membrane and the retina and to confirm the long-term efficacy and safety of this approach in persistent macular hole and eventually in other retinal pathologies. Further developments are also needed to improve this technique and to determine the best timing for the patch removal when needed.

## References

- Morizane Y, Shiraga F, Kimura S, Hosokawa M, Shiode Y, Kawata T, et al. Autologous transplantation of the internal limiting membrane for refractory macular holes. *Am J Ophthalmol.* 2014;157(4):861-9.e1.
- Grewal DS, Mahmoud TH. Autologous neurosensory retinal free flap for closure of refractory myopic macular holes. *JAMA Ophthalmol.* 2016;134(2):229-30.
- Chen SN, Yang CM. Lens capsular flap transplantation in the management of refractory macular hole from multiple etiologies. *Retina.* 2016;36(1):163-70.
- Peng J, Chen C, Jin H, Zhang H, Zhao P. Autologous lens capsular flap transplantation combined with autologous blood application in the management of refractory macular hole. *Retina.* 2018;38(11):2177-83.
- Rahman I, Said DG, Maharajan VS, Dua HS. Amniotic membrane in ophthalmology: indications and limitations. *Eye (Lond).* 2009;23(10):1954-61.
- Ohno-Matsui K, Ichinose S, Nakahama K, Yoshida T, Kojima A, Mochizuki M, et al. The effects of amniotic membrane on retinal pigment epithelial cell differentiation. *Mol Vis.* 2005;11:1-10.
- Rizzo S, Caporossi T, Tartaro R, Finocchio L, Franco F, Barca F, et al. A Human amniotic membrane plug to promote retinal breaks repair and recurrent macular hole closure. *Retina.* 2019;39 Suppl 1:S95-103.
- Moharram HM, Moustafa MT, Mortada HA, Abdelkader ME. Use of epimacular amniotic membrane graft in cases of recurrent retinal detachment due to failure of myopic macular hole closure. *Ophthalmic Surg Lasers Imaging Retina.* 2020;51(2):101-8.
- Tsai DC, Huang YH, Chen SJ. Parafoveal atrophy after human amniotic membrane graft for macular hole in patients with high myopia. *Br J Ophthalmol.* 2021;105(7):1002-10.
- Lee SM, Kwon HJ, Park SW, Lee JE, Byon IS. Microstructural changes in the fovea following autologous internal limiting membrane transplantation surgery for large macular holes. *Acta Ophthalmol.* 2018;96(3):e406-8.