

Case Report

Uterine Leiomyosarcoma in a Young Unmarried Lady- A Case Report

Begum Monowara*, Begum Tahmina, Zihan Nazia and Hossain Shahlee

Department of Oncology, Evercare Hospital Dhaka, Bangladesh

Abstract

Leiomyosarcoma of the uterus is a very rare malignancy. It arises from the smooth muscles of the uterus. Very few cases on uterine leiomyosarcoma have been published so far. We report a case of a 23-year-old unmarried female who was having severe menorrhagia and was diagnosed later as a case of uterine leiomyosarcoma. The final diagnosis of leiomyosarcoma was made by histopathology. The only curative treatment of leiomyosarcoma of the uterus is surgery. The prognosis completely depends on the extension and histological characteristics like mitotic index, during the time of diagnosis.

Keywords: Leiomyosarcoma of the uterus; Menorrhagia; Uterine malignancy

Introduction

Leiomyosarcoma of the uterus is a very rare malignancy. Its prevalence is only 1%-2% of the uterine malignancy especially after the menopause. It arises from the smooth muscle of the uterus. They are highly aggressive in nature and carry very poor prognosis. At the same time, it is very difficult to define the treatment modalities due to its diverse pathological presentations which often creates diagnostic dilemma. We report a case of a 23-year-old unmarried female who was having severe menorrhagia and was diagnosed later as a case of uterine leiomyosarcoma after the surgical intervention.

Case Presentation

A 23-year-old unmarried Bangladeshi lady was admitted through the OPD of Evercare Hospital Dhaka on 6 September, 2020 as a diagnosed case of fibroid uterus. She had severe menorrhagia which started since November, 2019. During this period, she was transfused several units of blood. She had not suffered either from any long-term illness or from any chronic disease. She had no family history of such malignancies.

On examination

Patient was ill looking but cooperative. Her body built was normal. She was hemodynamically stable. She was mildly anemic. Per abdominal examination, uterus was palpable about 14 week's size of pregnant uterus. The mass was mobile which non tender was. The overlying skin was normal. Per vaginal examination was not done as she was unmarried.

Investigations

Full blood count showed that hemoglobin was 11.0 gm/dl, WBC was $9.35 \times 10^9/L$ and Platelet was $705 \times 10^9/L$. On ultrasonography dated 26 August 2020, uterus was bulky measuring about 15.0 cm \times 5.5 cm. Fairly large mixed echogenic predominantly hypoechoic focal lesion involving the whole cervix and lower part of the body of the uterus measuring about 8.5 cm \times 5.3 cm (Figure 1). Endometrium was thickened about 20.1 mm. Both the ovaries were normal.

She was planned for laparoscopic surgery. On 7 September 2020, she underwent laparo-hysteroscopic myomatous polypectomy and specimen was sent for histopathology which revealed leiomyosarcoma (Grade-I). Staging CT chest and abdomen were unremarkable.

Operative findings

She underwent laparoscopic procedure and hysteroscopic resection of myomatous polyp. During laparoscopic procedure, uterus was found enlarged about 14 weeks size and bulged over the posterior uterine wall, both the fallopian tubes and ovaries were looking healthy. Intracapsular vasopressin was injected through posterior uterine wall. A small incision was given over the lower part of posterior uterine wall to get reach of myoma. But finally planned laparoscopic procedure was abandoned. Later we approached per vaginally. Her vaginal examination revealed a large degenerative myomatous polyp about 8 cm \times 6 cm protruding through cervix and occupying the whole vagina. It was friable. This large polyp was arising from lower part of uterus and cervix and was attached to uterine wall with broad pedicle. The myoma was excised per vaginally though complete removal was not possible. Then hysteroscope was introduced for resection of rest of the polyp and was sent for histopathology. Histopathology report showed leiomyosarcoma. On 14 September 2020, she underwent total abdominal hysterectomy, bilateral salpingo-oophorectomy with pelvic lymph node sampling. Uterus was bulky in size. Frozen section biopsy was sent. It was found negative for malignancy. Uterus with both adnexa and pelvic lymph nodes were sent for histopathological examination.

On histopathological examination

Anaplastic spindle epithelioid cells showed marked pleomorphism with many mitotic figures (Figure 2a,b). It was diagnosed to be a case

Citation: Monowara B, Tahmina B, Nazia Z, Shahlee H. Uterine Leiomyosarcoma in a Young Unmarried Lady-A Case Report. *J Surg Surgic Case Rep.* 2021;2(2):1018.

Copyright: © 2021 Begum Monowara

Publisher Name: Medtext Publications LLC

Manuscript compiled: Aug 11th, 2021

***Corresponding author:** Begum Monowara, Senior Consultant and Coordinator, Department of Oncology, Evercare Hospital Dhaka, Bangladesh, E-mail: monowara.begum25@gmail.com

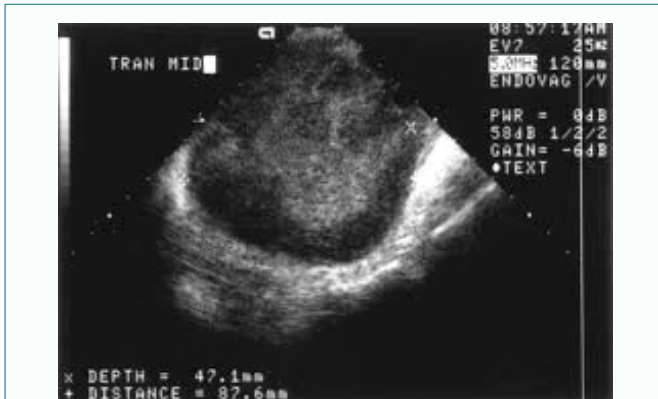

Figure 1: Ultrasonogram of the uterus showing fibroid.

of leiomyosarcoma (high grade). Lympho-vascular invasion was not identified.

Postoperative period

The postoperative period was uneventful. The patient was discharged after five days.

Discussion

Leiomyosarcoma of the uterus is an uncommon malignancy. Its account for only 1%-2% of the uterine cancer. The annual incidence is only 0.64 per 100,000 women. Leiomyosarcoma can occur anywhere in the pelvic cavity including the cervix and urinary bladder. But it is more commonly developed in the uterus which was also seen in our case [1]. Mostly occur in post-menopausal women over the age of 60 who usually develop abnormal vaginal bleeding (56%), palpable lower abdominal mass (54%) as well as pain (22%). It sometimes may resemble with the leiomyoma and often very difficult to distinguish between the two tumors before the surgery [2]. The patient presented with the complaints of severe menorrhagia. Uterine fibroids do not usually turn into malignant leiomyomas. Leiomyosarcomas may coexist within the fibroid uterus. About 0.5% of the hysterectomy cases for uterine fibroids are having leiomyosarcomas [3]. It is very difficult to diagnose leiomyosarcoma accurately without surgery. Because leiomyosarcoma of the uterus is associated with multiple fibroids and most of the time it is difficult to identify which ones should be biopsied [4]. Magnetic Resonance Imaging (MRI) might

help in the diagnosis but less accurate. Leiomyosarcoma of the uterus are very aggressive in nature with high rates of recurrence. It develops from the myometrium or a vessels. The diagnosis of uterine sarcoma is confirmed by histological examination of entire uterus as seen in our case. The recommended treatment is total hysterectomy. But bilateral salpingo-oophorectomy and lymph nodes are not recommended since lymph nodes involvement is very rare [5]. It is commonly spread by hematogenous route. Lymphatic spread is very rare. Up to 70% of recurrences occur in stage I and II disease. The most of the recurrences occur distally that is in the upper abdomen or lungs [6-8]. The rate of survival closely depends on the stage of disease at times of diagnosis. Fifty percent of the patients with stage I disease usually survive five years on the other hand only 8%-12% with stage II-IV disease survive five years [7]. Overall, the five-year survival rate is about 30%-50%. Patients with local recurrences can be managed with surgery. Isolated pulmonary metastasis can also be treated by resection [9].

References

1. Corcoran S, Hogan AM, Nemeth T, Bennani F, Sullivan FJ, Khan W, et al. Isolated cutaneous metastasis of uterine leiomyosarcoma: case report and review of literature. *Diagn Pathol.* 2012;7:85.
2. D'Angelo E, Prat J. Uterine sarcomas: a review. *Gynecol Oncol.* 2010;116(1):131-9.
3. Harry VN, Narayansingh GV, Parkin DE. Uterine leiomyosarcomas: a review of the diagnostic and therapeutic pitfalls. *Obstet Gynaecol.* 2007;9(2):88-94.
4. Reichardt P. The treatment of uterine sarcomas. *Ann Oncol.* 2012;23 Suppl 10:x151-7.
5. Sagae S, Yamashita K, Ishioka S, Nishioka Y, Terasawa K, Mori M, et al. Preoperative diagnosis and treatment results in 106 patients with uterine sarcoma in Hokkaido, Japan. *Oncology.* 2004;67(1):33-9.
6. Denschlag D, Masoud I, Stanimir G, Gilbert L. Prognostic factors and outcome in women with uterine sarcoma. *Eur J Surg Oncol.* 2007;33(1):91-5.
7. Salazar OM, Dunne ME. The role of radiation therapy in the management of uterine sarcomas. *Int J Radiat Oncol Biol Phys.* 1980;6(7):899-902.
8. Gadducci A, Sartori E, Landoni F, Zola P, Maggino T, Cosio S, et al. The prognostic relevance of histological type in uterine sarcomas: a cooperation task force (CTF) multivariate analysis of 249 cases. *Eur J Gynaecol Oncol.* 2002;23(4):295-9.
9. Levenback C, Rubin SC, McCormack PM, Hoskins WJ, Atkinson EN, Lewis JL Jr. Resection of pulmonary metastases from uterine sarcomas. *Gynecol Oncol.* 1992;45(2):202-5.

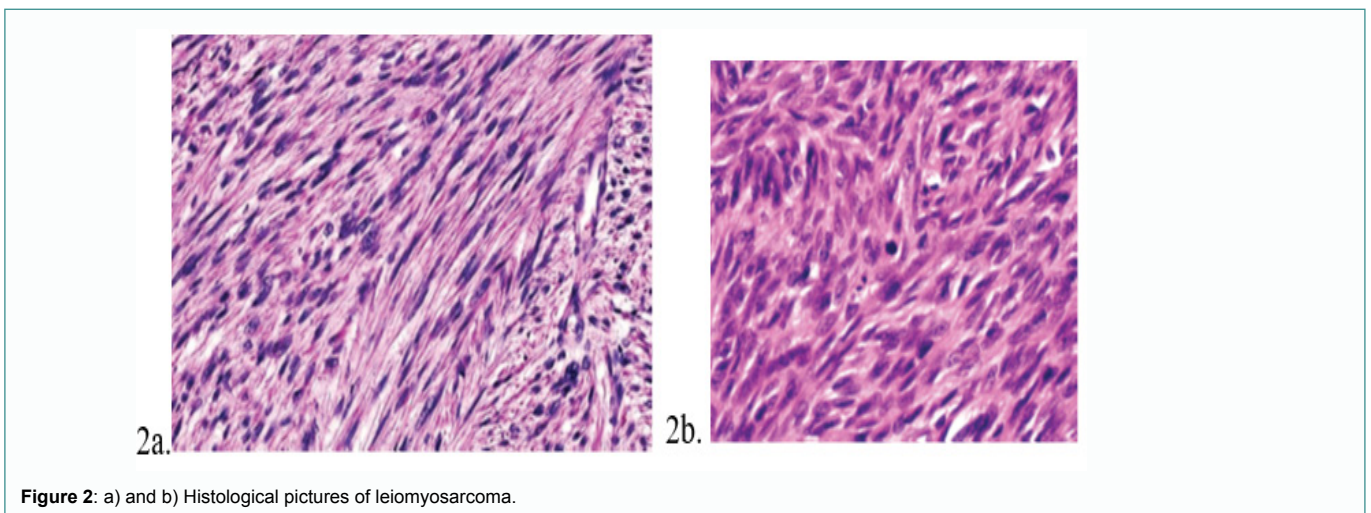


Figure 2: a) and b) Histological pictures of leiomyosarcoma.