

Research Article

Visual Damage of 37 Cases after Methanol Poisoning in Yemen

Mahfouth Bamashmus^{1,2*} and Najeeb Al-Kershy²

¹Department of Eye, Sana'a University, Republic of Yemen

²Department of Eye, Magrabi Eye Hospital, Republic of Yemen

Abstract

Objective: Yemen prohibits alcohol and some patients take methanol instead and develop methanol poisoning. We present the visual sequelae of methanol poisoning based on cases seen in Yemen Magrabi Eye Hospital. Outbreaks of methanol poisoning occur on and off affecting vulnerable.

Methods: A retrospective case-series was performed reviewing 37 case files between 2012 and 2019 with methanol poisoning. The objectives were to describe the characteristics and outcome of a methanol poisoning to the vision. The following tests were performed: complete ocular examination (visual acuity and fundus), fundus photo, Optical Coherence Tomography (OCT) with evaluation of the Retinal Nerve Fibers Layer (RNFL) and Visual Evoked Potentials (VEP).

Results: All 37 patients were young or middle-aged males and the median age was 39 (range, 20 to 62) years. No female patient was seen. All patients admitted drinking unbranded alcohol (methanol or cologne) two to three days before presentation. All patients had optic atrophy and cupping bilaterally after three months. 30/37 (81.1%) had long term visual problems with 70.3% blind. Mean visual acuity in this group was counting fingers at 2 meters in the best corrected eye (logMAR 1.7; range 0.7 - 2.00) with some eye to eye variability within individuals.

Conclusion: Majority of patients deny taking methanol in the first few days. Methanol poisoning causes visual loss within 12 to 48 hours due to severe painless bilateral optic nerve damage. In Yemen, where diagnostic resources are limited, use of active case finding can help in the management of methanol poisonings.

Keywords: Blindness; Methanol poisoning; Optic nerve damage; Yemen

Introduction

Methanol is clear and colorless liquid and is found in cologne and perfumes and is used in industry such as antifreeze and wiper fluid [1]. It tastes same as ethanol and it is cheap and easy to obtain and it is used in production of illegal alcoholic beverages [2]. Mass poisoning of methanol is relatively uncommon and happens sporadically and methanol-related deaths have been reported in literature [3-5]. It typically occurs in developing countries or in countries with high taxes on alcohol. The illegal spirits can contain pure methanol and can be mixed with ethanol or handmade alcohol [1]. In Yemen there is a legal prohibition on distribution and sale of alcohol and methanol poisoning is largely due to the consumption of underground handmade alcoholic beverages.

Methanol poisoning occurs as epidemics leading to death or toxic optic neuropathy [4,6]. Unfortunately some cases die before reaching the emergency room. Isolated cases have been reported but are rare. Many reports describe the deadly effect of methanol toxicity ranging

between 8% to 36% [3-5]. Permanent loss of vision due to optic neuropathy is observed in 20% to 40% of patients that survive the acute incidence [4,5,7]. The vision loss is painless and occurs in both eyes with 24 hours and some patient's vision might improve [8].

In Yemen, methanol poisoning is becoming a serious and growing healthcare problem mostly involving young and middle aged males [9]. It is a medical emergency and it is important to rapidly block alcohol dehydrogenase to prevent the toxic effect of formic acid to the brain and optic nerve [10,11]. Formic acid is cytotoxic due its inhibition to mitochondrial cytochrome oxidases leading to cell hypoxia [10]. The visual problems are due to the toxic effect of formic acid and can be permanent or transient. Some patients present with long-term visual damage with reduced visual acuity or even blindness but other cases present with complete recovery and resolution of the changes of the optic disc with improvement of visual acuity [8,12].

Recognizing this potential threat, a national clinical guideline for treatment of methanol poisoning has to be developed by reviewing all outbreaks and recruiting principal medical directors in Yemen. Methanol toxicity can result in serious morbidity and mortality without timely diagnosis and treatment.

Outbreaks of methanol poisoning occur on and off affecting vulnerable people and many cases of methanol poisoning outbreaks have been noted in our population but no study has been performed to estimate methanol exposure and its outcomes and complications. The objectives of this study were to discuss the characteristics of optic nerve damage from methanol poisoning in 33 consecutive patients that presented to Yemen Magrabi Eye Hospital in Sana'a, Yemen.

Methods

A retrospective case series was performed reviewing 37

Citation: Bamashmus M, Al-Kershy N. Visual Damage of 37 Cases after Methanol Poisoning in Yemen. Clin Ophthalmol J. 2021;2(1):1016.

Copyright: © 2021 Mahfouth Bamashmus

Publisher Name: Medtext Publications LLC

Manuscript compiled: Jan 28th, 2021

***Corresponding author:** Mahfouth A Bamashmus, Department of Eye, Professor of Ophthalmology, Faculty of Medicine and Health Sciences, Sana'a University, Sana'a, P. O. Box 19576, Republic of Yemen, Tel: +967-733270277; Fax: +967-1210021; E-mail: bamashmus@hotmail.com

consecutive patients between January 2012 and June 2019 with methanol poisoning in Yemen Magrabi Eye Hospital in Sana'a, Yemen. All cases admitted of drinking unbranded alcohol or cologne within one to three days before presentation with bilateral painless visual loss. Information recorded included gender, age, occupation, visual acuity, optic disc appearance and other neurological signs.

The objectives were to describe the characteristics and outcome of a methanol poisoning to the vision. Visual sequelae of acute methanol poisoning persisting more than three months after their first visit when the acute pseudo-papillitis resolved and the edema of the optic nerve completely subsided. All patients were examined few days to one week after methanol intoxication and three months later. All had neurological evaluation before presentation or they were referred to a neurologist after the eye evaluation. Medical records of the 37 cases were reviewed.

Twenty patients before presentation to our hospital reported that they were admitted to an intensive care unit and nine had kidney dialysis. None of our group of patients received ethanol or fomepizole.

The following tests were performed: fundus photo, Optical Coherence Tomography (OCT) with evaluation of the Retinal Nerve Fibers Layer (RNFL), Visual Evoked Potentials (VEP), Magnetic Resonance Imaging (MRI) of brain and complete ocular examination (visual acuity and fundus). If documentation was inadequate for evaluation and diagnosis the case was excluded from the study. Statistical analysis was performed using Statistical Package for Social Sciences version 21 (SPSS Inc., Chicago, IL, USA). Snellen acuity was converted to the logarithm of the minimum angle of resolution (logMAR) for statistical analysis.

Ethical approval was obtained from the Research Department of Yemen Magrabi Eye Hospital.

Results

A total of 37 patients presented to the ophthalmic clinic. All 37 patients were young or middle-aged males and the median age was 39 (range, 20 to 62) years. No female patient was seen. Seventeen patients underwent hemodialysis. All patients admitted drinking unbranded alcohol (methanol or cologne) two to three days before presentation.

All patients at presentation reported acute bilateral painless visual loss. The visual loss was profound and majority presented with visual acuity of perception of light or no perception of light. Most patients on presentation had complete eye exam, fundus photo, Optical Coherence Tomography (OCT) of the optic disc and Visual Evoked Potential (VEP). Before presentation most patients had MRI or CT scan of the brain elsewhere as they were all admitted to an intensive care unit after having severe vomiting or loss of consciousness after the toxicity. Those who did not have a brain imaging they were referred for an MRI or CT scan of the brain.

30/37 (81.1%) had long term visual problems with 70.3% blind. Mean visual acuity in this group was counting fingers at 2 meters in the best corrected eye (logMAR 1.7; range 0.7 - 2.00) with some eye to eye variability within individuals.

Fundoscopy photo of the optic disc of a patient two days after the methanol toxicity is presented in Figure 1. The pictures show optic disc swelling and edema with peripapillary edema. All examined cases had optic atrophy and cupping bilaterally after the 3 months visit. The fundoscopic appearance of the same patient, taken three months after

methanol exposure showing optic disc cupping and pallor (Figure 2). Most patients had normal neurological examination.

Discussion

In Yemen ethanol is prohibited but it is smuggled and sold in the black market. Sometimes methanol is adjusted and mixed with water or ethanol and sold to vulnerable people. Every few months an epidemic of methanol toxicity affects a group of people and large epidemics of death and visual loss have happened in Sana'a and Aden but usually the authorities do not announce it on the media [9]. Most of them die but some survive and are admitted to the intensive care unit. Hospitalized patients present as single patient and not as part of affected group after 12 to 48 hours because of confusion, coma, abdominal pain and blurred vision. Usually patients do not admit drinking alcohol especially in the presence of family members. In such situations patients are questioned several times regarding the event before the visual loss and are better to be questioned when family members are not present or they are asked to leave the examination room.

Rapid treatment after accurate diagnosis of methanol poisoning prevents death and minimizes the optic nerve and brain damage. But the situation in the emergency room is usually complicated because the patient presents as an individual after hours of exposure, critically ill with incomplete or inaccurate history and non-specific symptoms

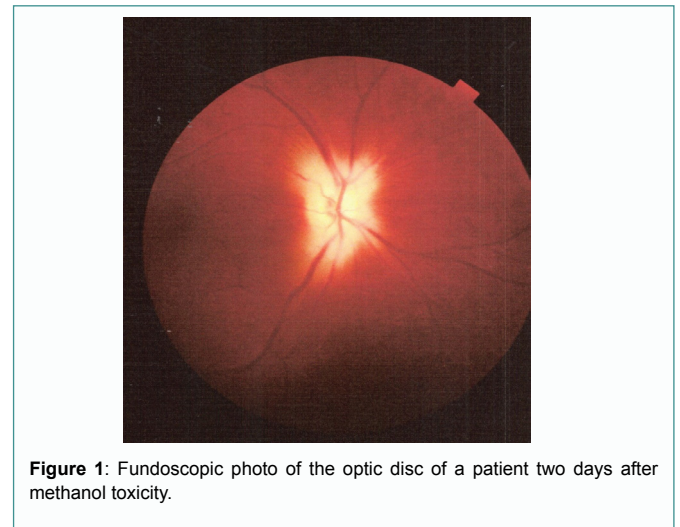


Figure 1: Fundoscopic photo of the optic disc of a patient two days after methanol toxicity.

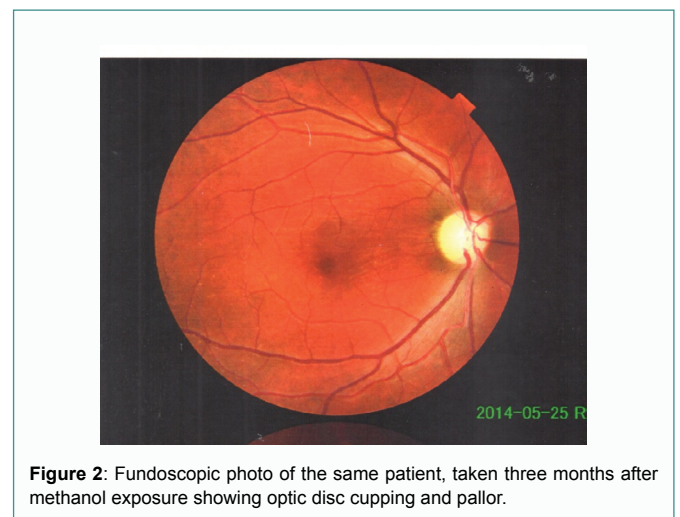


Figure 2: Fundoscopic photo of the same patient, taken three months after methanol exposure showing optic disc cupping and pallor.

Table 1: Characteristics of patients with methanol poisoning in Yemen.

Case	Age	Occupation	Governorate	OD	OS	DISC	Note
1	28	Doctor	Sana'a	20/40	20/35	Pale cupped disc	Hemodialysis
2	23	Soldier	Albaida	CF 10 cm	CF 1 M	Pale cupped disc	
3	55	Retired	Sana'a	POL	POL	Pale cupped disc	
4	38	Teacher	Sana'a	20/70	CF 1 M	Pale cupped disc	
5	20	Soldier	Sana'a	POL	CF 2 M	Pale cupped disc	
6	35	Accountant	Sana'a	CF 20cm	CF 1 M	Pale cupped disc	
7	35	Businessman	Taiz	CF 3 M	CF 2 M	Pale cupped disc	
8	25	Businessman	Hodeidah	20/40	20/40	Pale cupped disc	Hemodialysis
9	45	Businessman	Sana'a	HM	HM	Pale cupped disc	
10	50	Employee	Sana'a	CF 20 cm	CF 40 cm	Pale cupped disc	Diabetes Mellitus
11	39	Unemployed	Sana'a	20/40	20/40	Pale cupped disc	Hemodialysis
12	39	Dentist	Sana'a	POL	20/100	Pale cupped disc	Hemodialysis
13	26	Dentist	Sana'a	CF 1 M	20/40	Pale cupped disc	Hemodialysis
14	45	Employee	Sana'a	20/400	20/400	Pale cupped disc	
15	40	Unemployed	Ibb	CF 1 M	CF 2 M	Pale cupped disc	
16	54	Businessman	Sana'a	CF 20 cm	CF 2 M	Pale cupped disc	HIV, Diabetes Mellitus
17	40	Businessman	Sana'a	HM	CF 1 M	Pale cupped disc	
18	47	Dentist	Sana'a	POL	CF 3 M	Pale cupped disc	
19	54	Retired	Sana'a	HM	CF 2 M	Pale cupped disc	
20	32	Accountant	Mareb	CF 50 cm	CF 1 M	Pale cupped disc	
21	43	Manager	Sana'a	POL	NPL	Pale cupped disc	
22	62	TV EMPLOYEE	Sana'a	POL	HM	Pale cupped disc	
23	45	Teacher	Dhamar	NPL	HM	Pale cupped disc	
24	46	Businessman	Hodeidah	20/50	20/70	Pale cupped disc	Hemodialysis
25	23	Soldier	Albaida	CF 10 cm	CF 1 M	Pale cupped disc	
26	41	Businessman	Sana'a	NPL	POL	Pale cupped disc	Diabetes Mellitus
27	39	Businessman	Hodeidah	HM	CF 2 M	Pale cupped disc	Diabetes Mellitus
28	31	Dentist	Sana'a	POL	POL	Pale cupped disc	
29	56	Retired	Hodeidah	CF 2M	CF 2 M	Pale cupped disc	
30	32	Doctor	Sana'a	20/70	20/70	Pale cupped disc	Hemodialysis
31	41	Employee	Sana'a	20/200	20/200	Pale cupped disc	Hemodialysis
32	27	Teacher	Aden	POL	CF 2 M	Pale cupped disc	
33	37	Engineer	Aden	HM	HM	Pale cupped disc	
34	33	Accountant	Lahj	CF 1 M	CF 1 M	Pale cupped disc	
35	31	Unemployed	Hajja	20/400	20/400	Pale cupped disc	Hemodialysis
36	23	Soldier	Dhamar	CF 1M	CF 1 M	Pale cupped disc	
37	26	Engineer	Sana'a	HM	CF 2 M	Pale cupped disc	

and signs. The emergency room doctor should have a high level of suspicion to elicit the history and recognizing metabolic acidosis with the presence of progressive visual loss [13]. Sometimes patients report that a friend had died unexpectedly when they were in the same party.

Unfortunately patients that have presented to us were not correctly diagnosed and only nine received dialysis for acidosis and none received fomepizole or ethanol as an antidote. Twenty five patients received intravenous methylprednisolone on the provisional diagnosis that visual loss was due to optic nerve inflammation [14]. Usually the ophthalmologic examination provides extremely useful information in such scenario. The symptoms of papillitis persist for few weeks and subside completely after two to three months and the long-term changes of retinal nerve fiber layer can be estimated after two months [8].

Methanol is non-toxic chemical but its metabolism in the liver to formaldehyde and formic acid are the toxic chemicals to the optic nerve and brain [12]. Formic acid invades cells and inhibits aerobic metabolism leading to metabolic acidosis which can be fatal [10]. Formic acid is selective to the optic nerve where it inhibits cytochrome oxidases in the laminar and retro-laminar regions of the optic nerve [15].

The primary priority in the treatment is restoration of normal pH to prevent formic acid entry into cells and this will improve recovery and survival of the optic nerve [5]. This is usually achieved

by hemodialysis and sodium bicarbonate to treat metabolic acidosis [13]. Systemic treatment is by oral or intravenous ethanol which is competitive inhibitor of liver alcohol dehydrogenase which is the first step in methanol metabolism [15]. Recent management includes treatment of systemic acidosis, hemodialysis, folate supplementation and fomepizole which is an aldehyde dehydrogenase inhibitor [13,16]. Folate and its derivatives have long been used as an adjunctive treatment in methanol poisoning [17]. Vitamin B1 and intravenous prednisolone improves the final visual outcome [14].

Methanol is lethal and the dose that can kill a person is considered to be 30 ml of 40% methanol [6]. A smaller dose of methanol does not kill but causes optic nerve toxicity and leads to sudden blindness. There is usually susceptibility variation between individuals where a small dose in one person can be very toxic while it has no effect in another person or have limited effect [6].

It is still not clear why distal optic nerve is vulnerable but it might be due to relatively high metabolic rates or that formic acid may accumulate in higher concentration than elsewhere [7]. Symptoms may resolve within few weeks and fundoscopic appearance of the optic neuropathy disappears within two to three months and long-term visual complications can be underestimated [7].

After the survival of this life-threatening episode all patients present to the ophthalmologist with bilateral painless visual loss due to optic nerve toxicity. We present 37 consecutive patients presented

to Yemen Magrabi Eye Hospital after visual loss due to methanol poisoning. All 37 patients were male, young to middle age, median age was 39 (range, 20 to 62) years. All presented within 24 hours to one week after the exposure to methanol.

The appearance of the optic disc in acute methanol poisoning is a hyperemic disc with edema of the peripapillary retina Figure 1. Sometimes cystoid macular edema and engorgement of retinal veins can be seen. After two to three months the optic nerve becomes pale and atrophic [7]. The optic atrophy can be with or without deep excavation of the disc especially after severe intoxication Figure 2.

Visual acuity was examined at the first presentation after days of the intoxication and three months after the exposure. Mean Visual Acuity (VA) was counting fingers at 2 meters. The visual loss can be partial or complete.

There are no guidelines addressing the public health aspects of methanol poisoning during larger outbreaks. Fortunately we did not have large out-brakes in Yemen except one in Aden in October 2018 [9].

In a recent study in Pakistan out of 35 patients, 19 (54.3%) patients expired secondary to methanol ingestion. All were male and the mean age was 36.2 ± 8.6 years. The mean Glasgow Coma Scale score on presentation in the emergency was 10.4 ± 4.4 . Blurring of vision was present in 17 (48%) patients while 10 (28%) had complete blindness. A total of 15 (42.8%) patients underwent dialysis, out of which only 5 (33.3%) patients survived [5]. A study in Iran regarding prognostic factors after methanol poisoning found that 48% of cases died and amongst survivors 23% developed blindness and 77% recovered without complication. Poor prognosis was associated with $\text{pH} < 7$, coma on admission and > 24 hours delay from intake to admission [11].

The main limitation to this study is that patients were not evaluated after the immediate acute intoxication in the emergency room or in the intensive care unit. Another limitation is a selection bias for those who recovered completely after the intoxication and did not seek ophthalmological evaluation.

In conclusion, the presentation of a young to middle aged man with acidosis, confusion, painless bilateral visual loss, abdominal discomfort with severe vomiting and loss of consciousness is very suspicious for methanol poisoning. The visual symptoms appear after 24 to 48 hours of ingestion and this is probably to the gradual accumulation of formic acid [12]. The visual loss is painless, severe and bilateral but sometimes is asymmetrical and usually gets better over the period of weeks after the exposure [18]. Majority of emergency rooms in the main hospitals have no guidelines to address the public health problems of methanol poisoning and this has to be addressed.

References

- Kraut JA. Diagnosis of Toxic Alcohols: Limitations of Present Methods. *Clin Toxicol (Phila)*. 2015;53(7):589-95.
- Chan APL, Chan TYK. Methanol as an Unlisted Ingredient in Supposedly Alcohol-Based Hand Rub Can Pose Serious Health Risk. *Int J Environ Res Public Health*. 2018;15(7):1440.
- Šejvl J, Barták M, Gavurová B, Mašlániová M, Petruželka B, Rogalewicz V, et al. Public Health Response to Methanol Mass Poisoning in the Czech Republic in 2012: a Case Study. *Cent Eur J Public Health*. 2019;27(Suppl):S29-39.
- Aghababaeian H, AraghiAhvazi L, Ostadtaghizadeh A. The Methanol Poisoning Outbreaks in Iran 2018. *Alcohol Alcohol*. 2019;54(2):128-30.
- Ahmed F, Khan NU, Ali N, Feroze A. Methanol Poisoning: 27 Years Experience at a Tertiary Care Hospital. *J Pak Med Assoc*. 2017;67(11):1751-2.
- Chng KL, Lai PS, Siew SF, MdYaro SW, Mahmood MS. Methanol Related Death in National Institute of Forensic Medicine, Hospital Kuala Lumpur: A Case Series. *Malays J Pathol*. 2020;42(1):99-105.
- Galvez-Ruiz A, Elkhamary SM, Asghar N, Bosley TM. Cupping of the Optic Disk After Methanol Poisoning. *Br J Ophthalmol*. 2015;99(9):1220-3.
- Sanaei-Zadeh H, Zamani N, Shadnia S. Outcomes of visual disturbances after methanol poisoning. *Clin Toxicol (Phila)* 2011;49(2):102-7.
- <https://al-arabi.com/s/27154>.
- Lukasik-Głębocka M, Sommerfeld K, Kapala M, Adamek R, Panieński P, Zielińska-Psuja B, et al. Usefulness of Blood Formic Acid Detection in the Methanol Poisoning in the Practice of Clinical Toxicology Department-Preliminary Assessment. *Przegl Lek*. 2014;71(9):475-8.
- Hassanian-Moghaddam H, Pajoumand A, Dadgar SM, Shadnia Sh. Prognostic Factors in Methanol Poisoning. *Hum Exp Toxicol*. 2007;26(7):583-6.
- Desai T, Sudhalkar A, Vyas U, Khamar B. Methanol poisoning: predictors of visual outcomes. *JAMA Ophthalmol*. 2013;131(3):358-64.
- Hovda KE, Froyshov S, Gudmundsdottir H, Rudberg N, Jacobsen D. Fomepizole may change indication for hemodialysis in methanol poisoning: prospective study in seven cases. *Clin Nephrol*. 2005;64(3):190-7.
- Sanaei-Zadeh H. Is high-dose intravenous steroid effective on preserving vision in acute methanol poisoning? *Optom Vis Sci*. 2012;89(2):244.
- Lee SL, Shih HT, Chi YC, Li YP, Yin SJ. Oxidation of methanol, ethylene glycol, and isopropanol with human alcohol dehydrogenases and the inhibition by ethanol and 4-methylpyrazole. *Chem Biol Interact*. 2011;191(1-3):26-31.
- Rietjens SJ, de Lange DW, Meulenbelt J. Ethylene Glycol or Methanol Intoxication: Which Antidote Should Be Used, Fomepizole or Ethanol?. *Neth J Med*. 2014;72(2):73-9.
- Theobald J, Lim C. Folate as an Adjuvant Therapy in Methanol Poisoning. *Nutr Clin Pract*. 2019;34(4):521-7.
- Galvez-Ruiz A, Elkhamary SM, Asghar N, Bosley TM. Visual and neurologic sequelae of methanol poisoning in Saudi Arabia. *Saudi Med J*. 2015;36(5):568-74.